

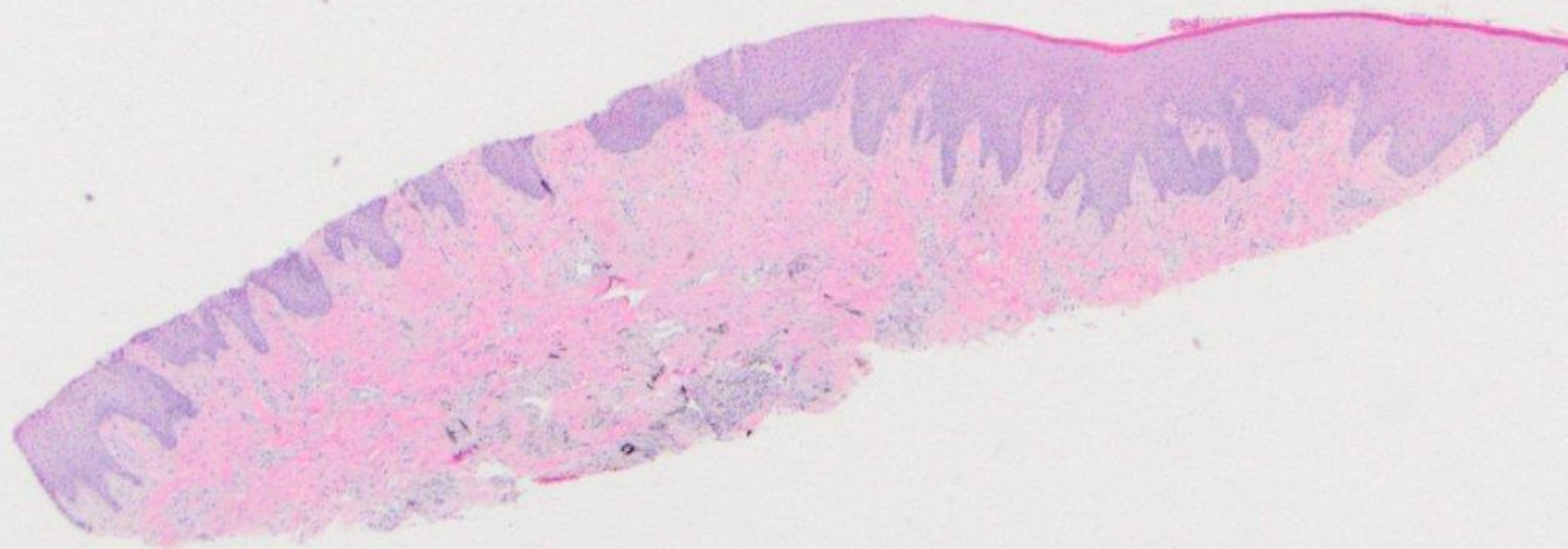
Oral Histopathology

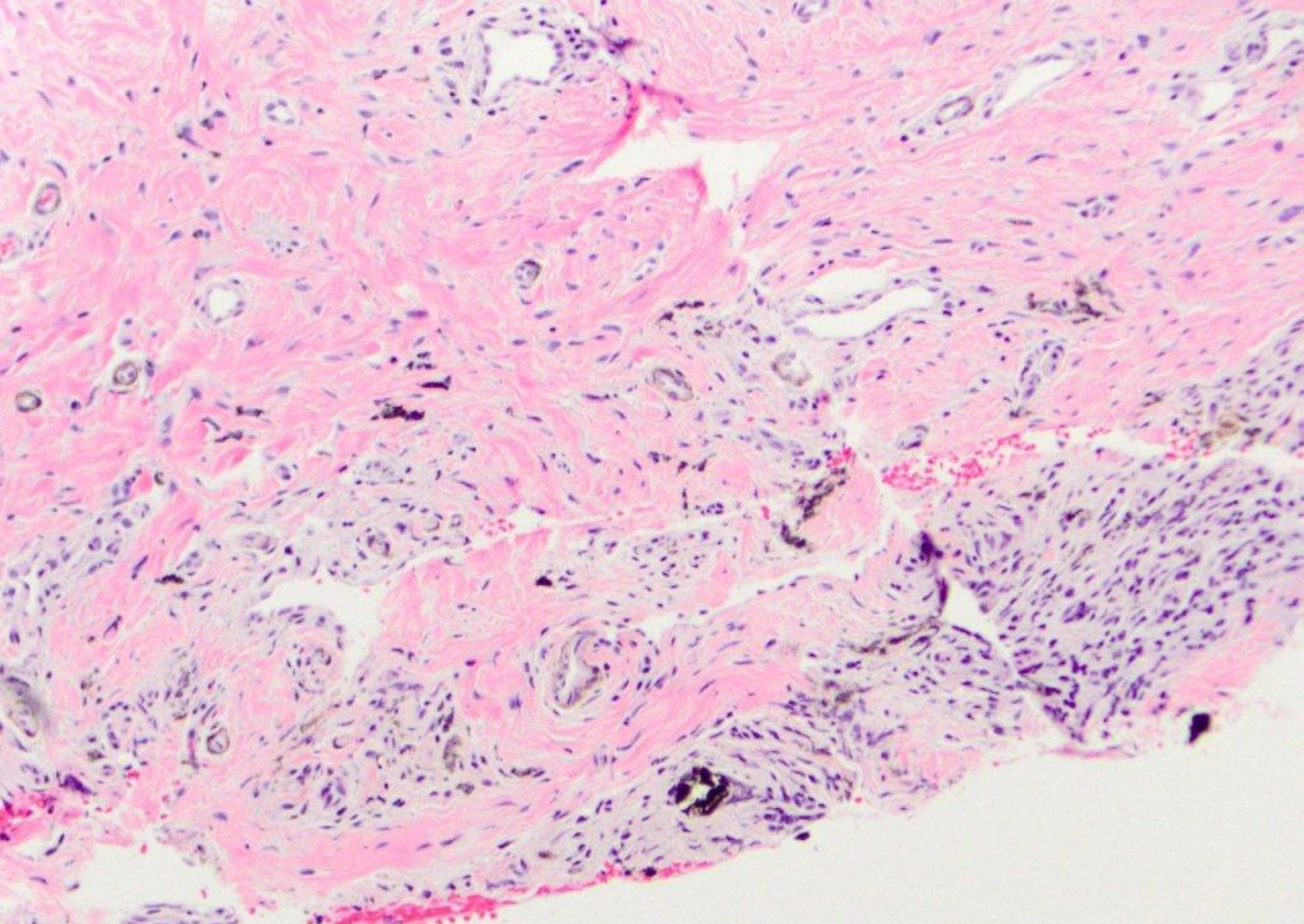
Series 43

DAVID E. KLINGMAN, DMD

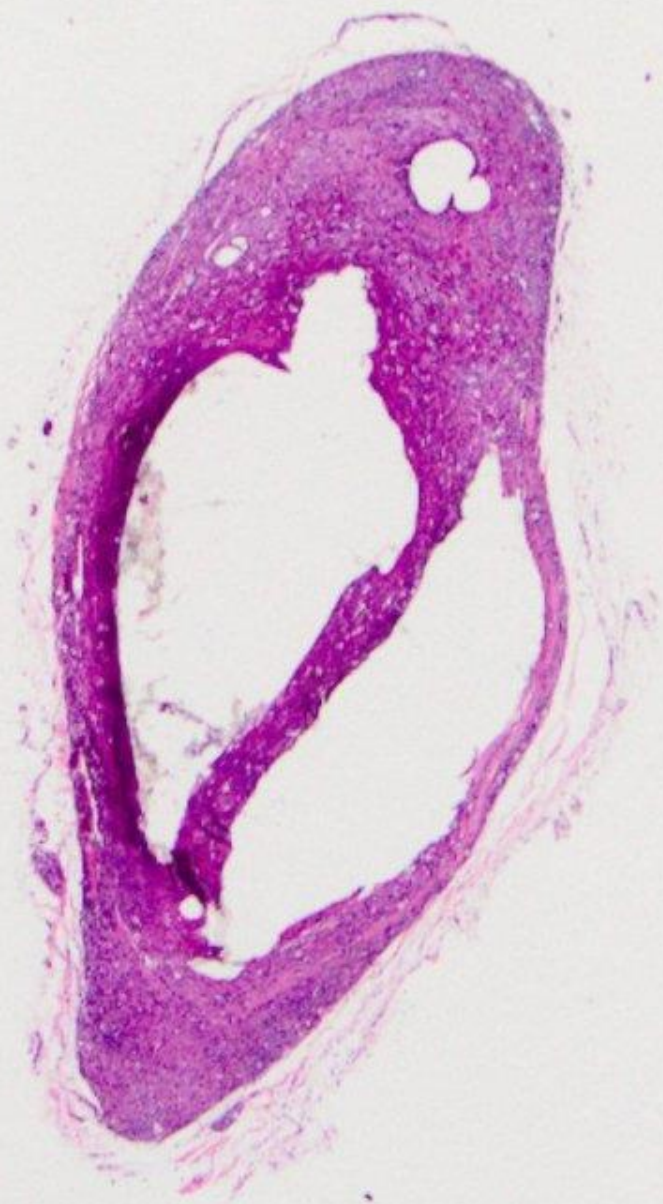
Diplomate, American Board of Oral and Maxillofacial Pathology

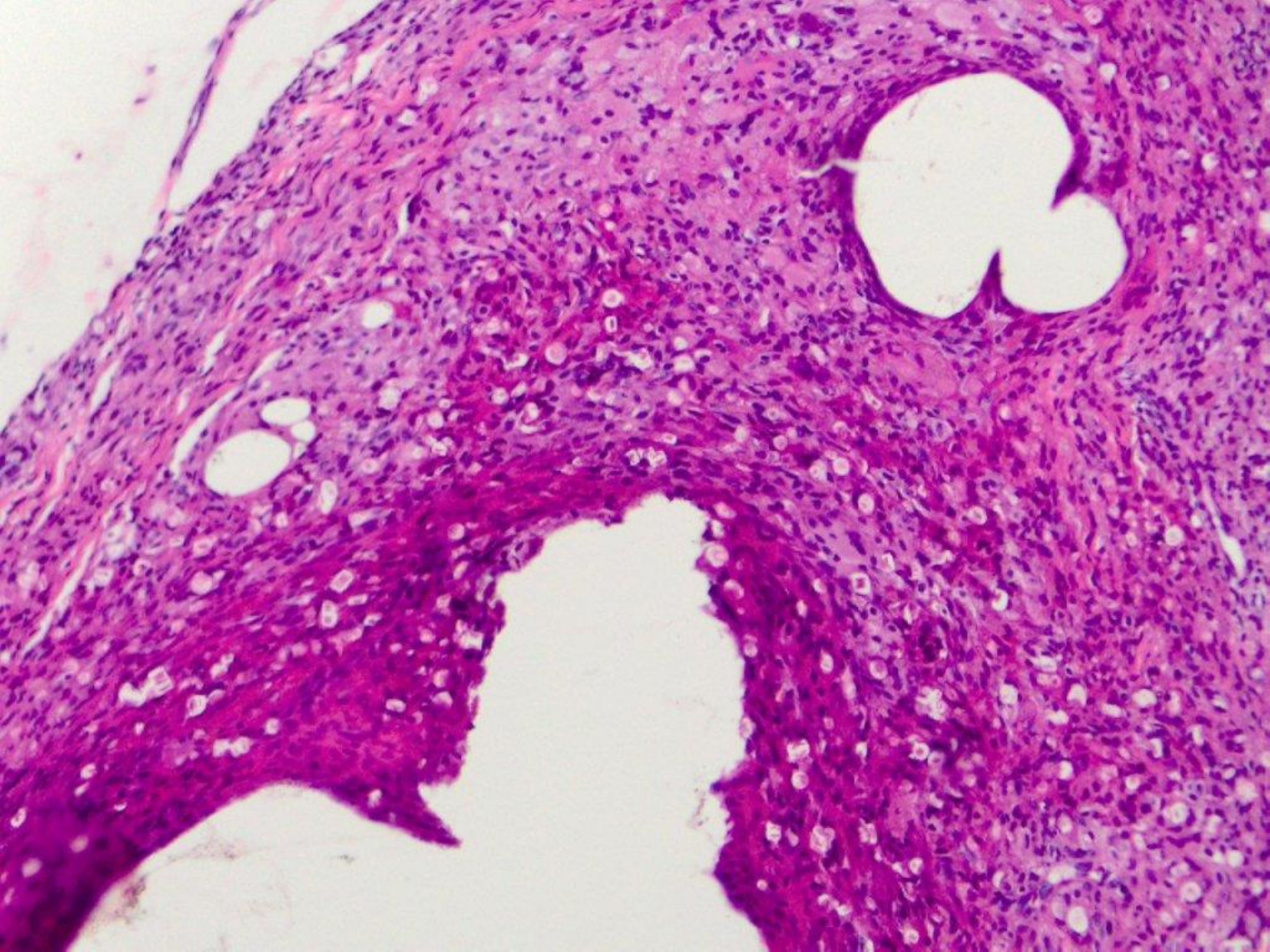
Diplomate, American Board of General Dentistry

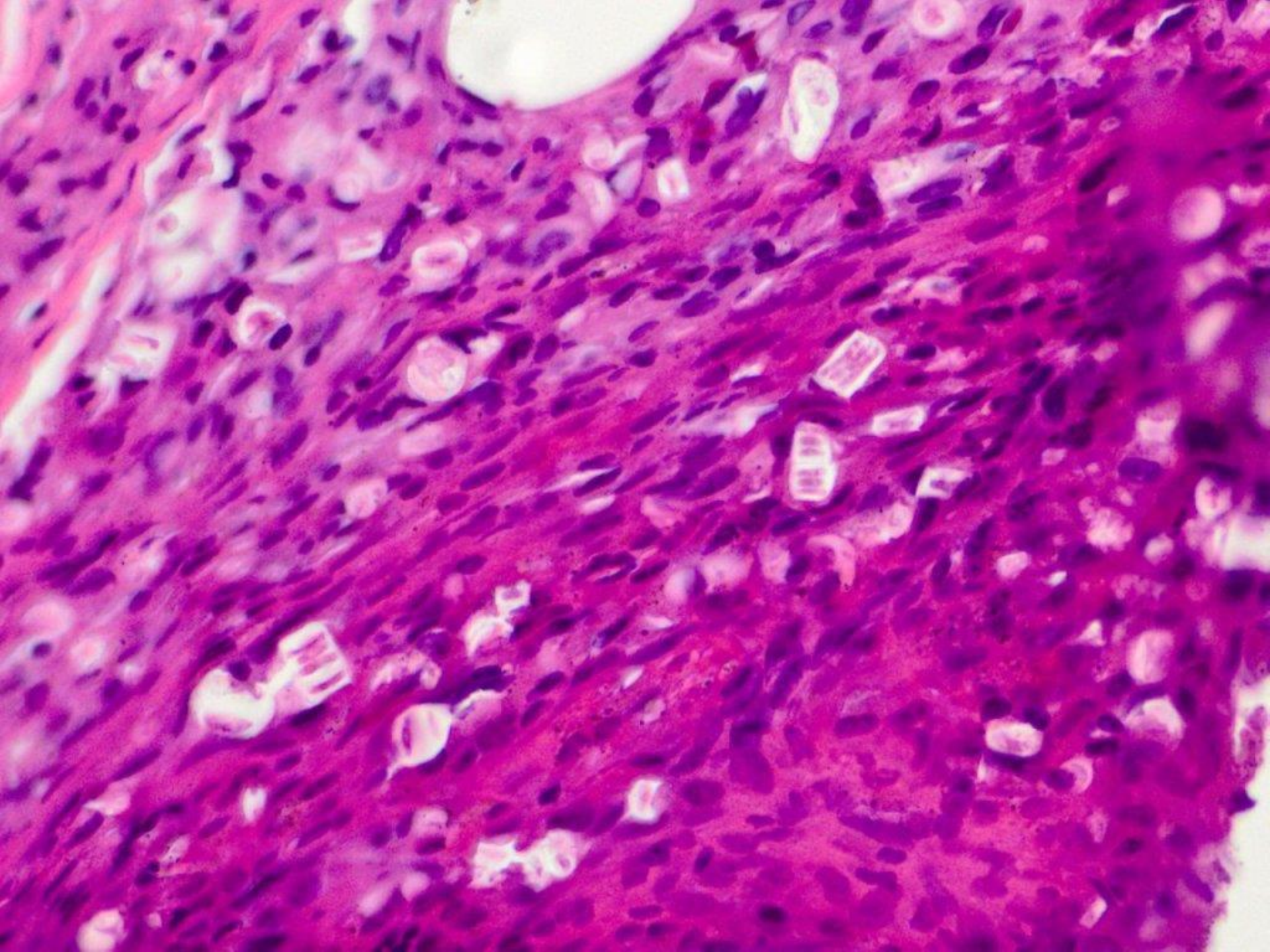


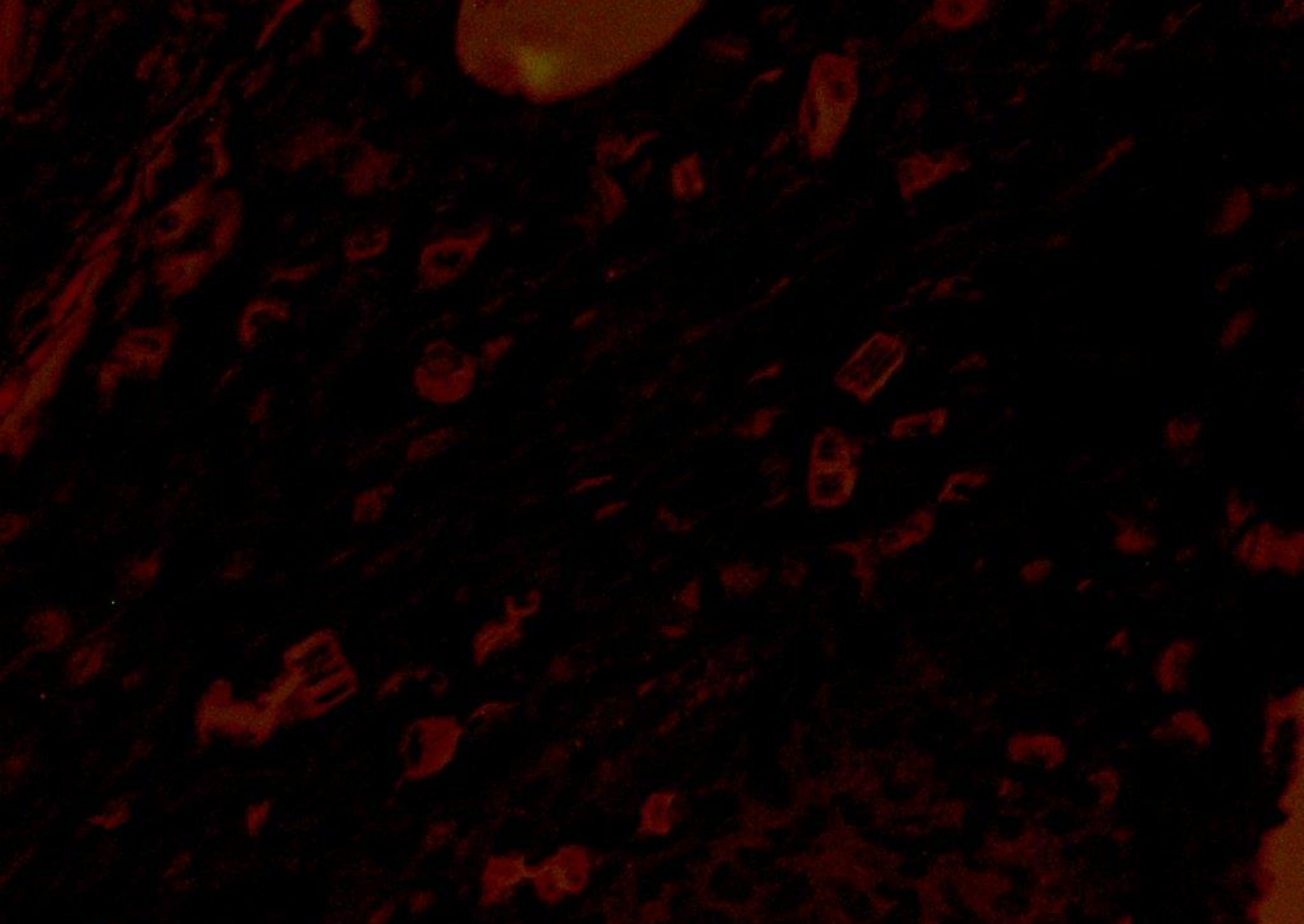

amalgam tattoo

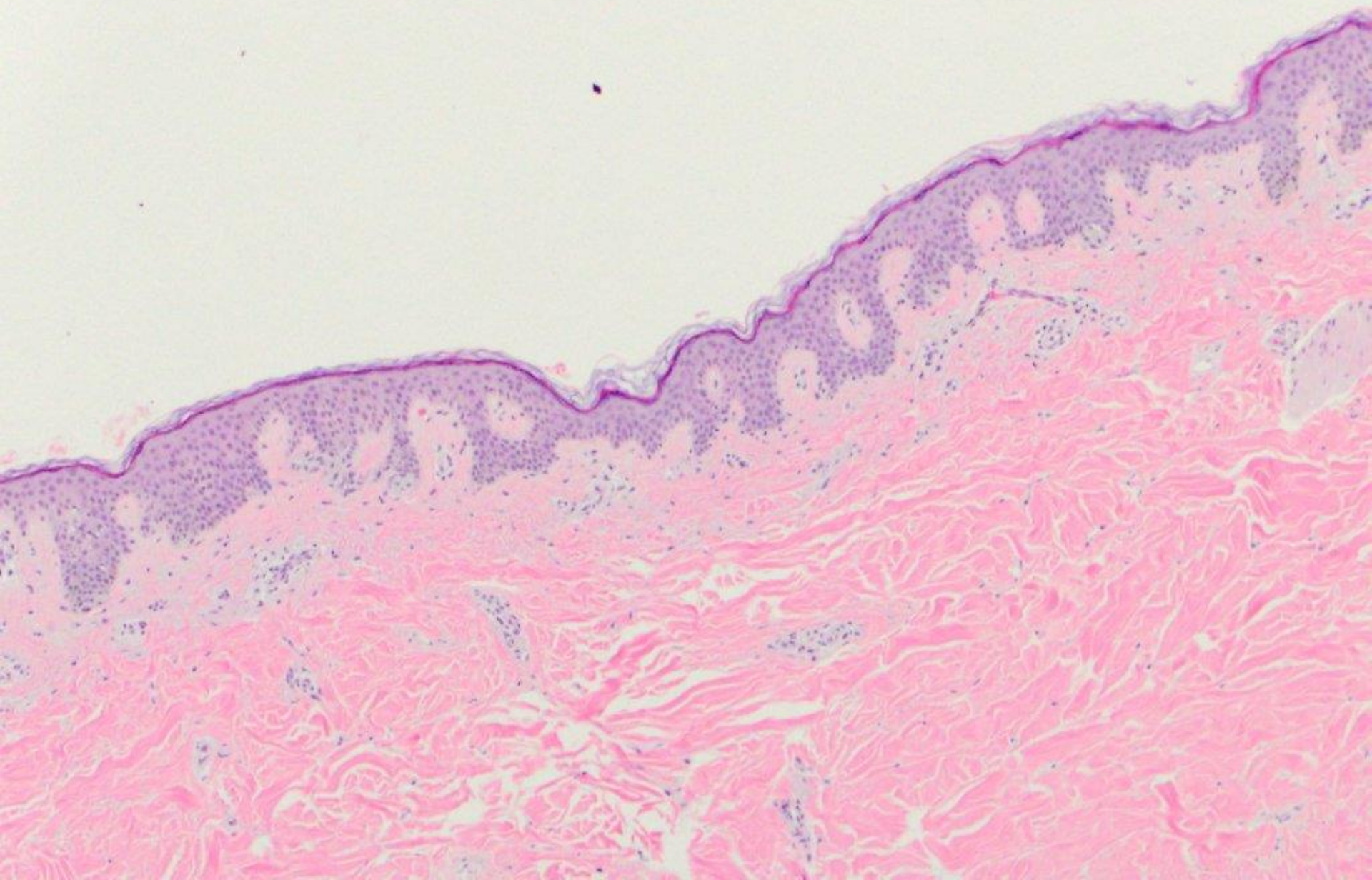


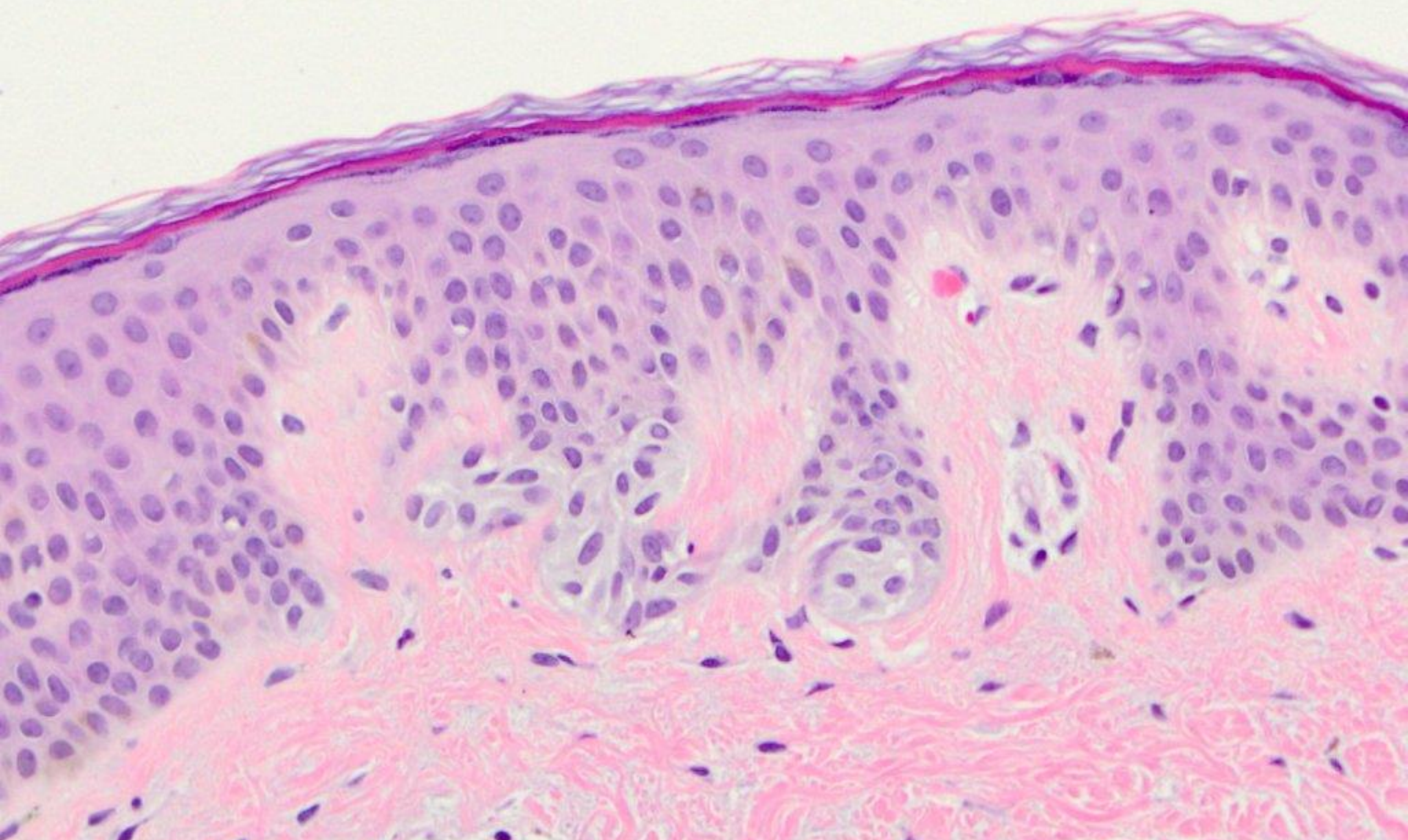




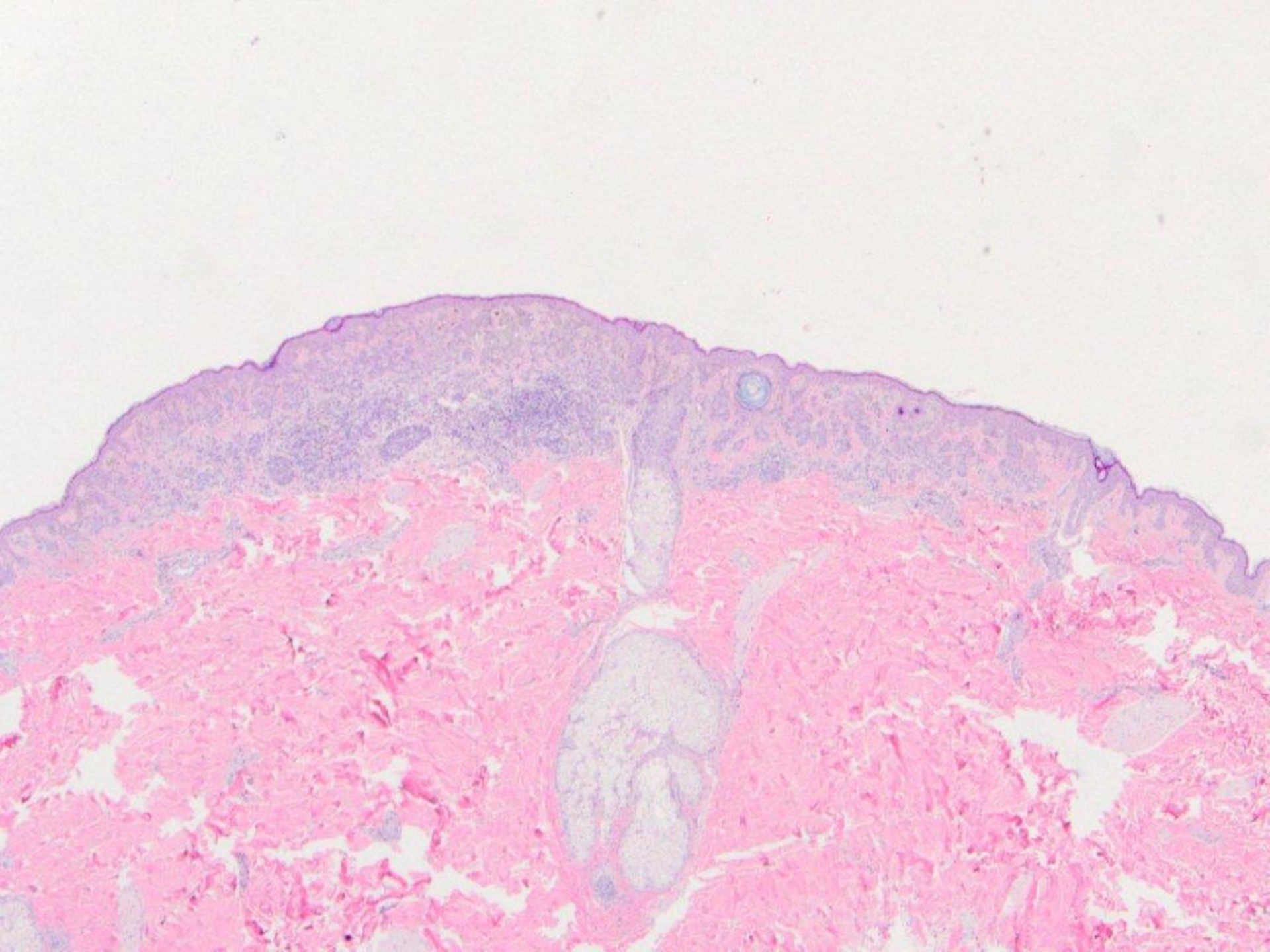


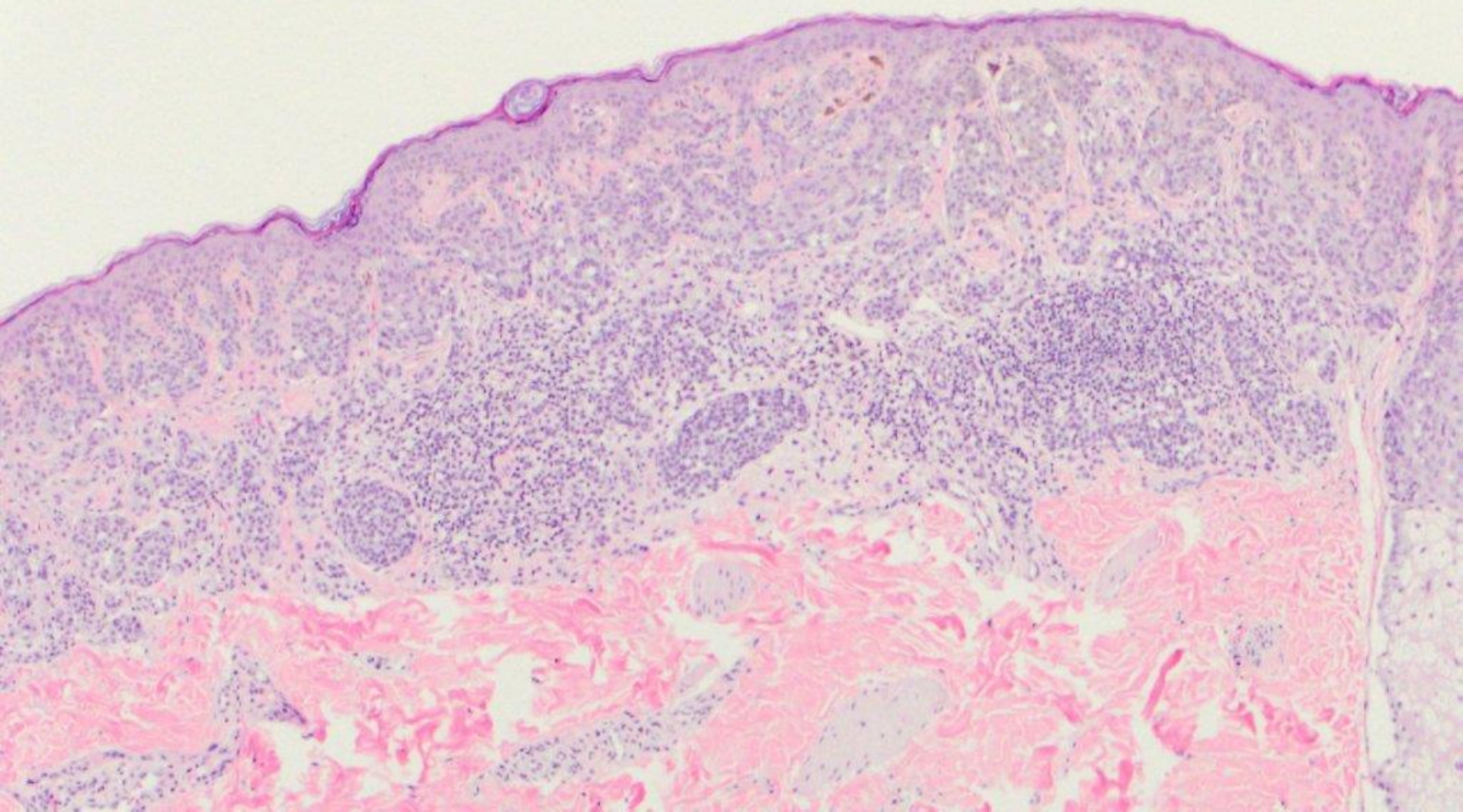
exogenous non-polarizable foreign material

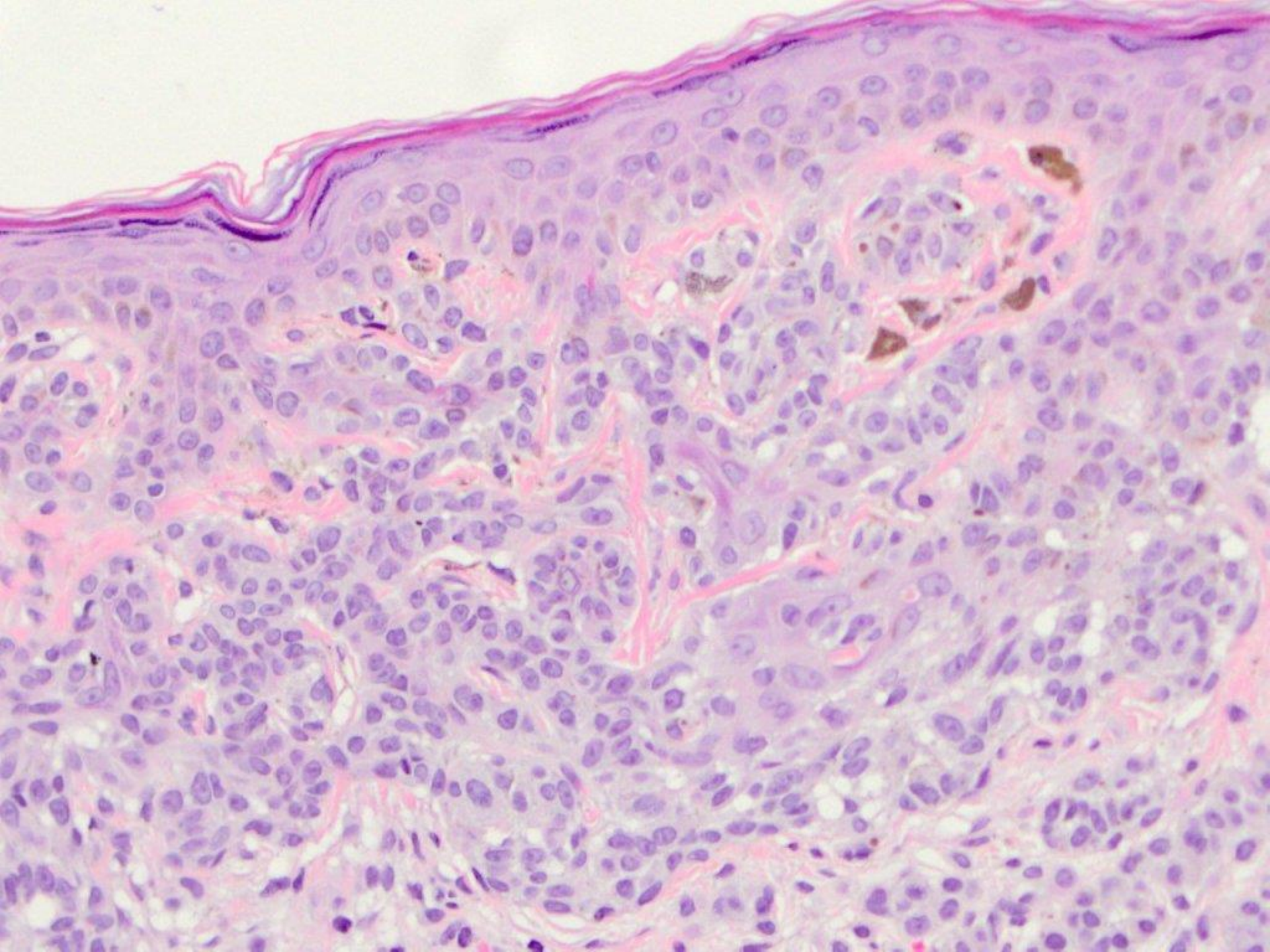


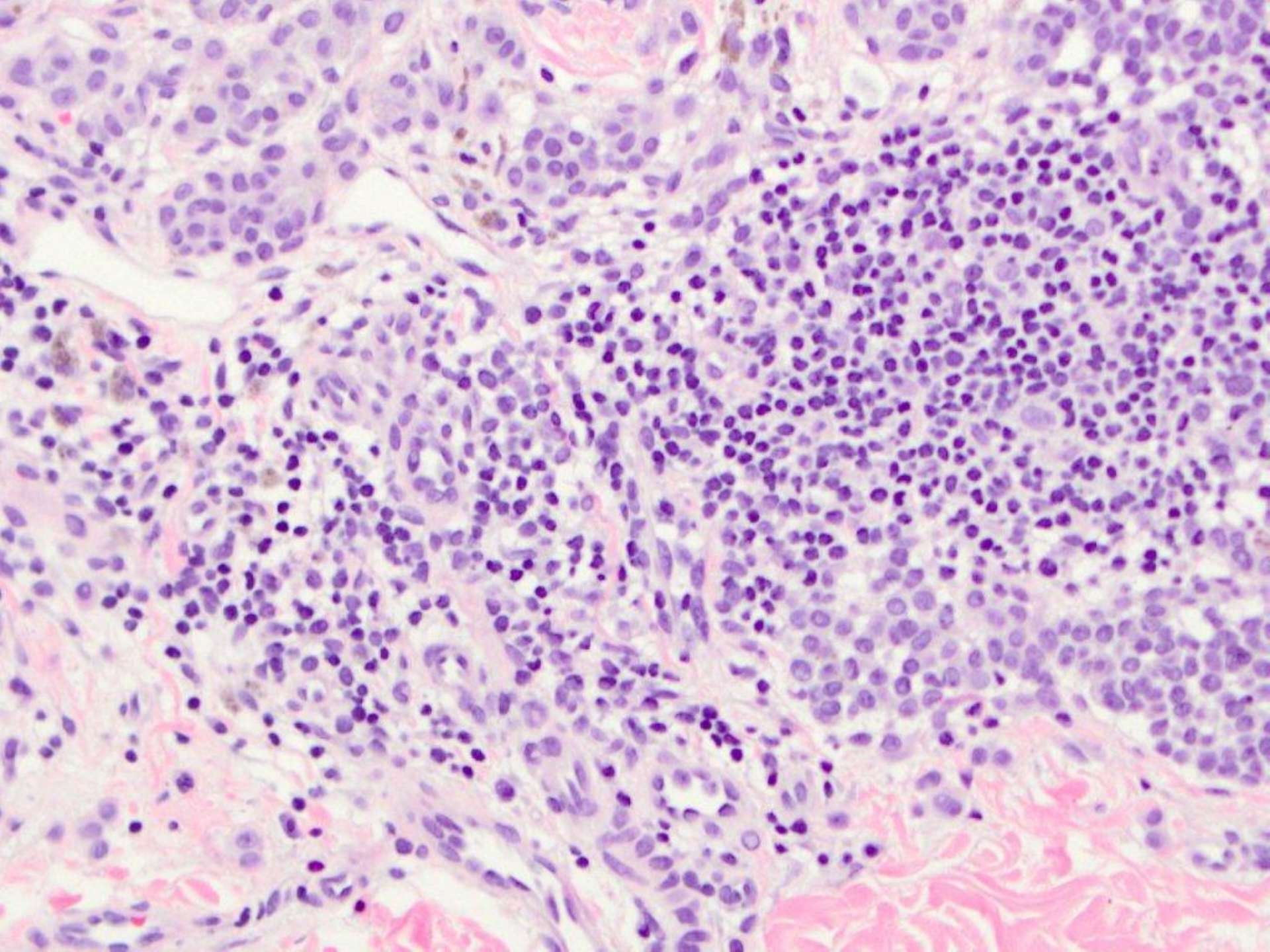


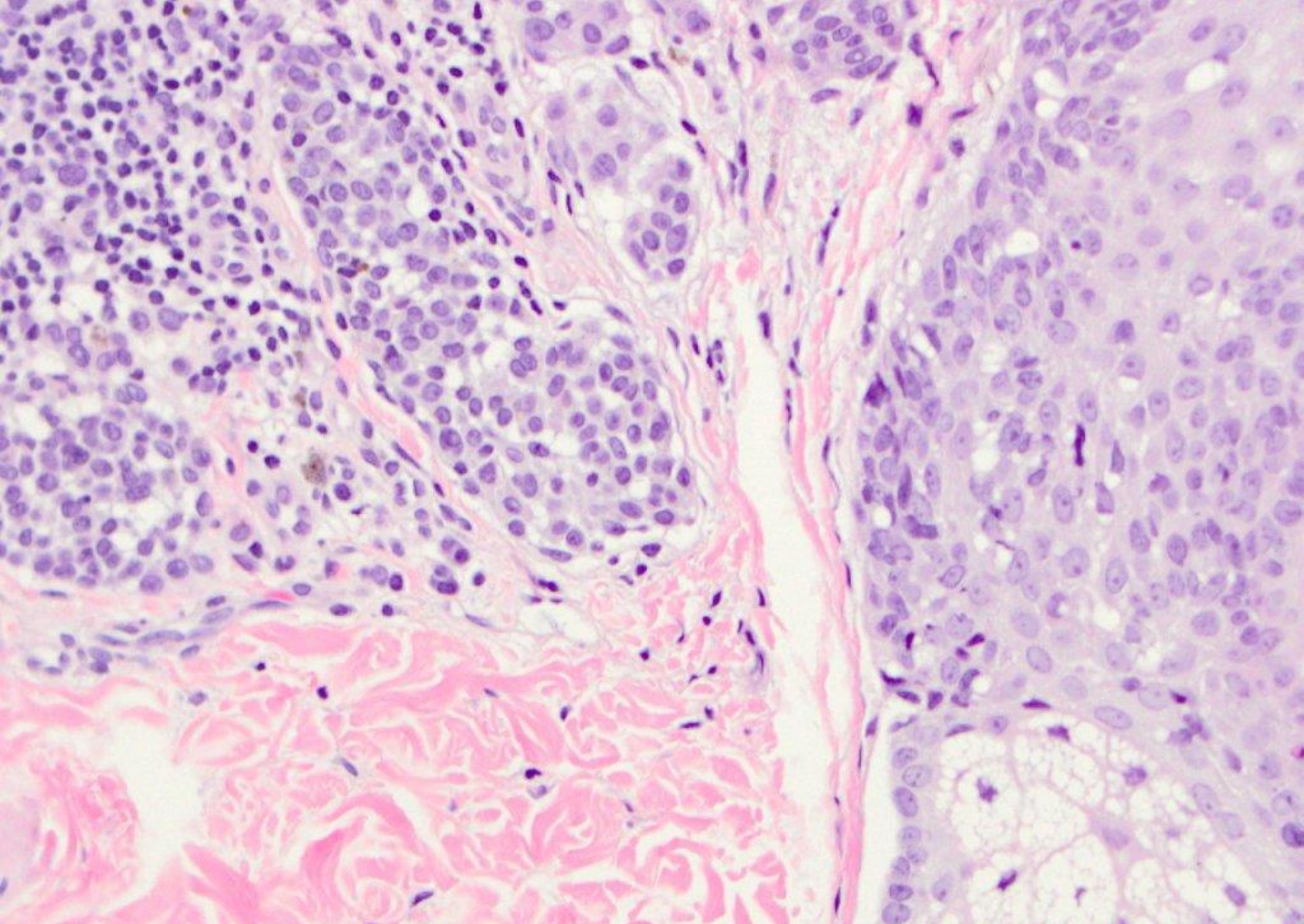
junctional melanocytic nevus



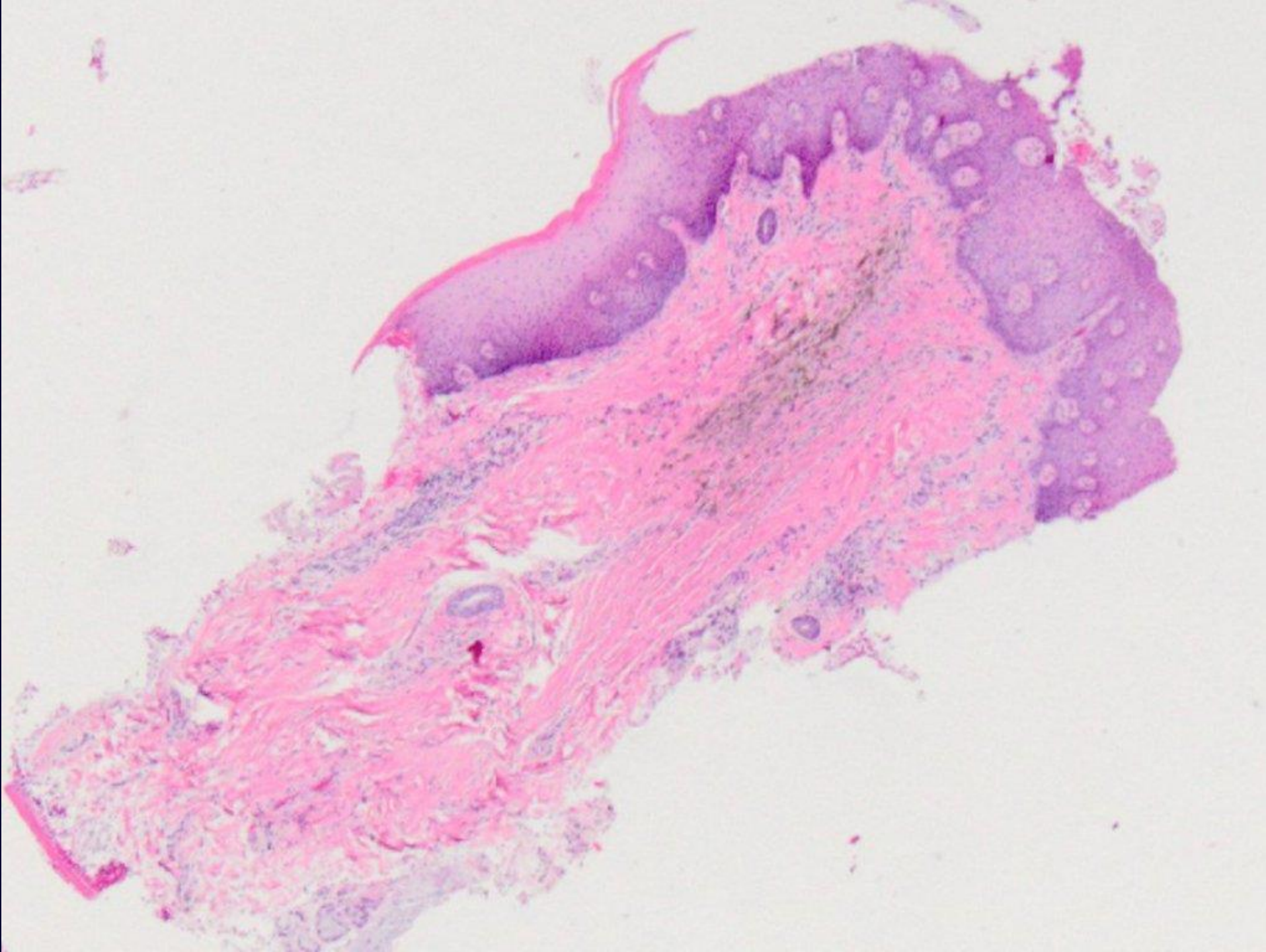


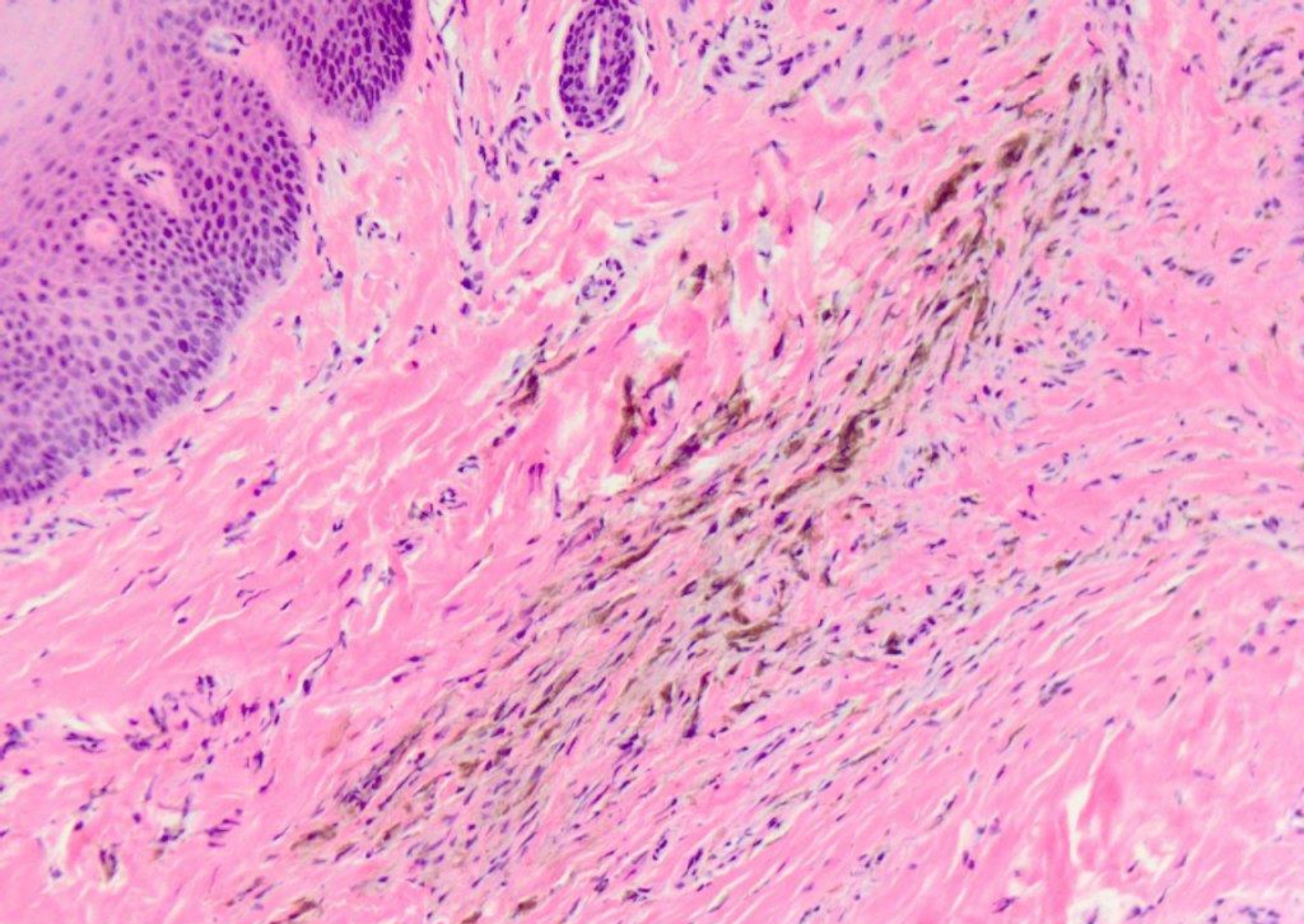




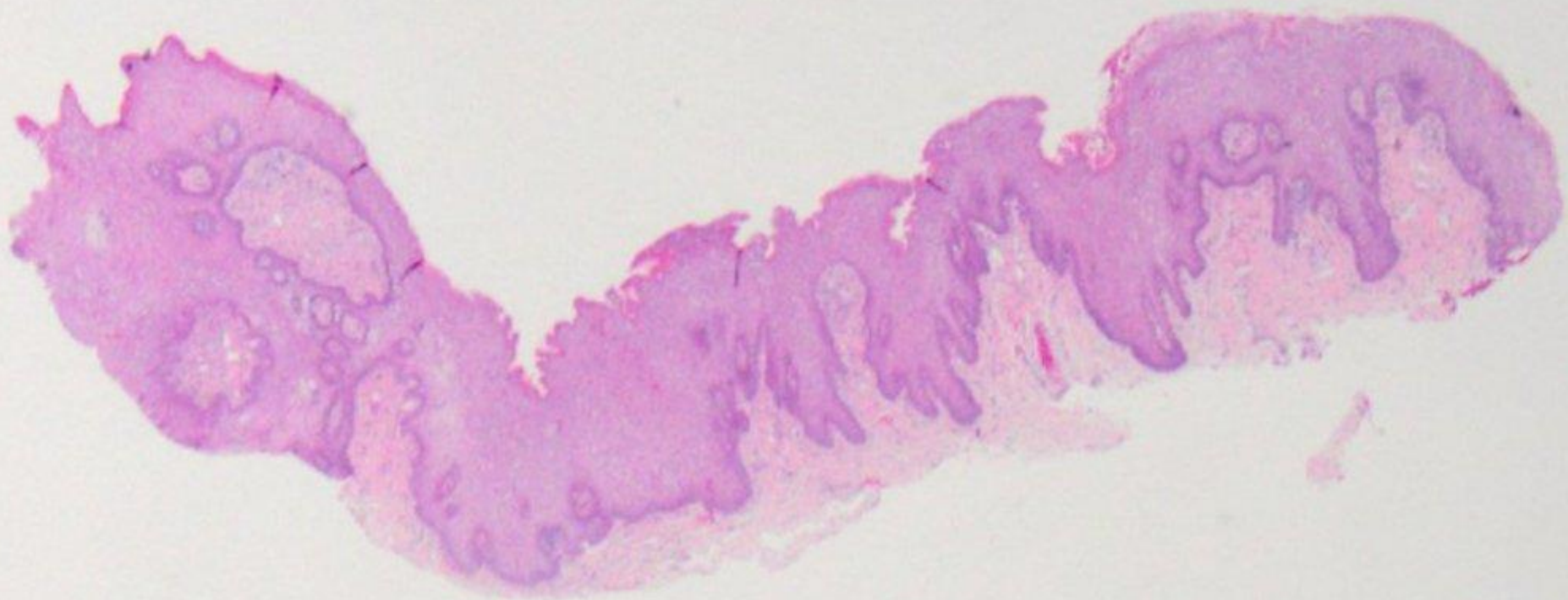


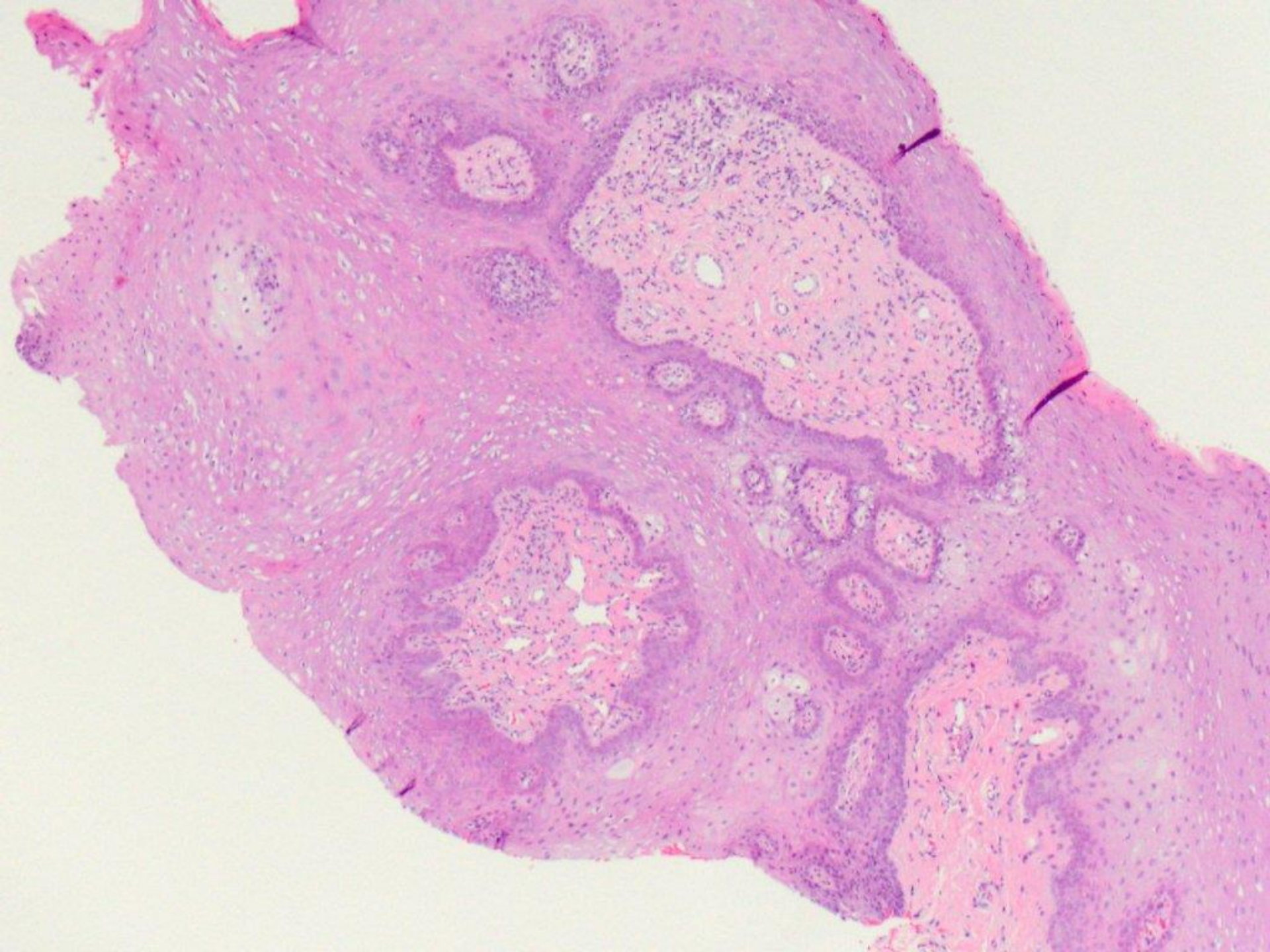
compund melanocytic nevus

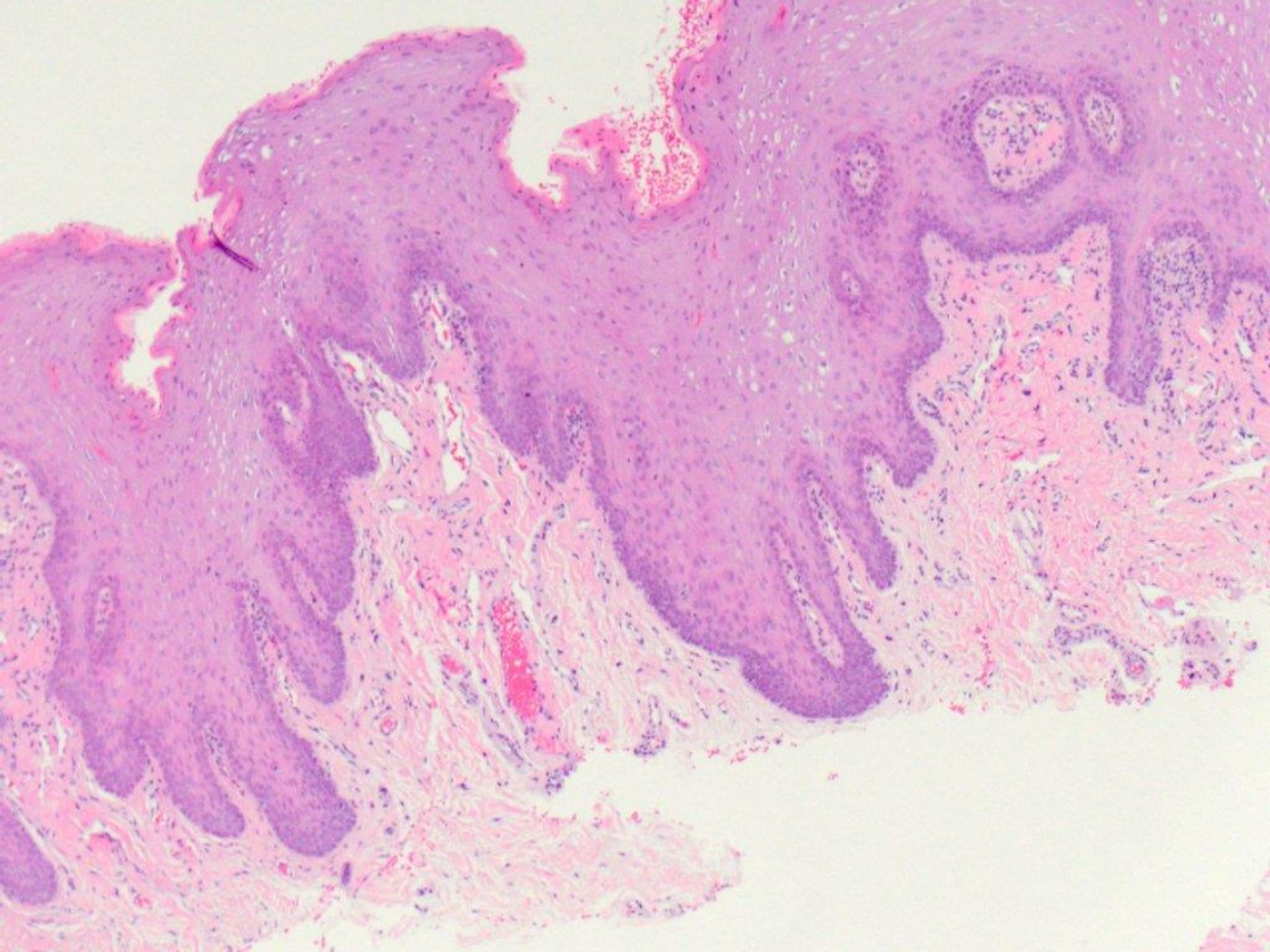


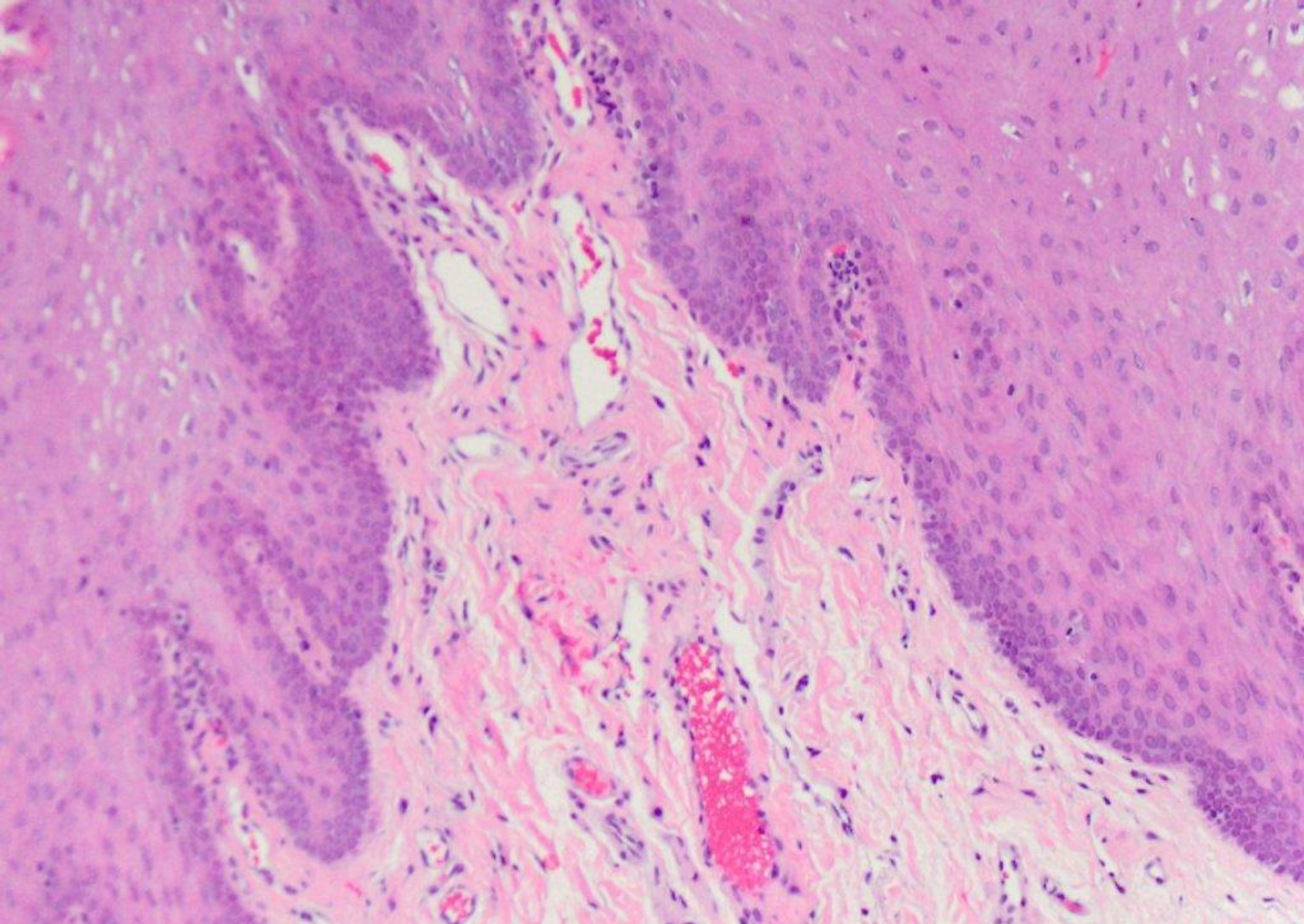


blue nevus

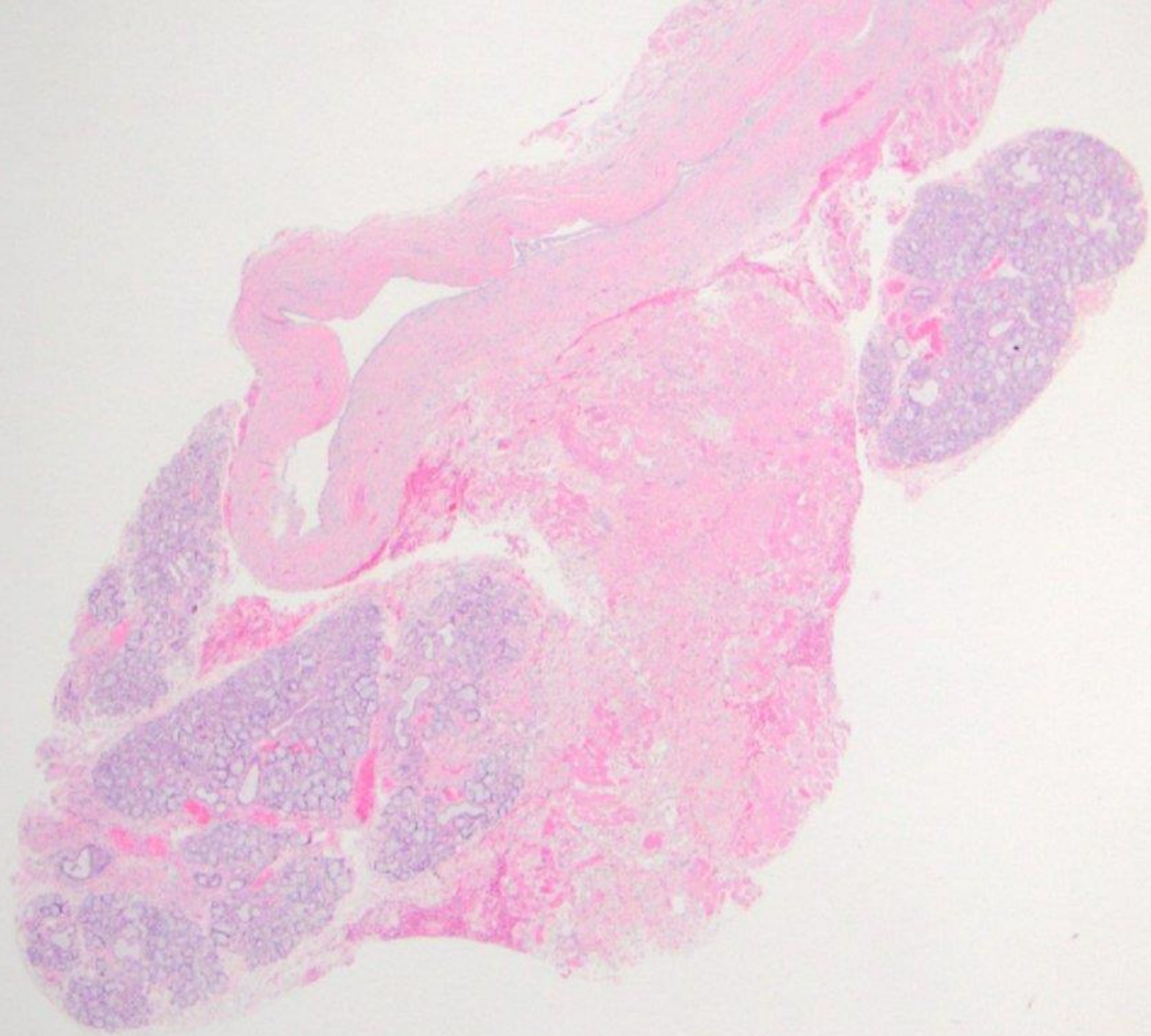


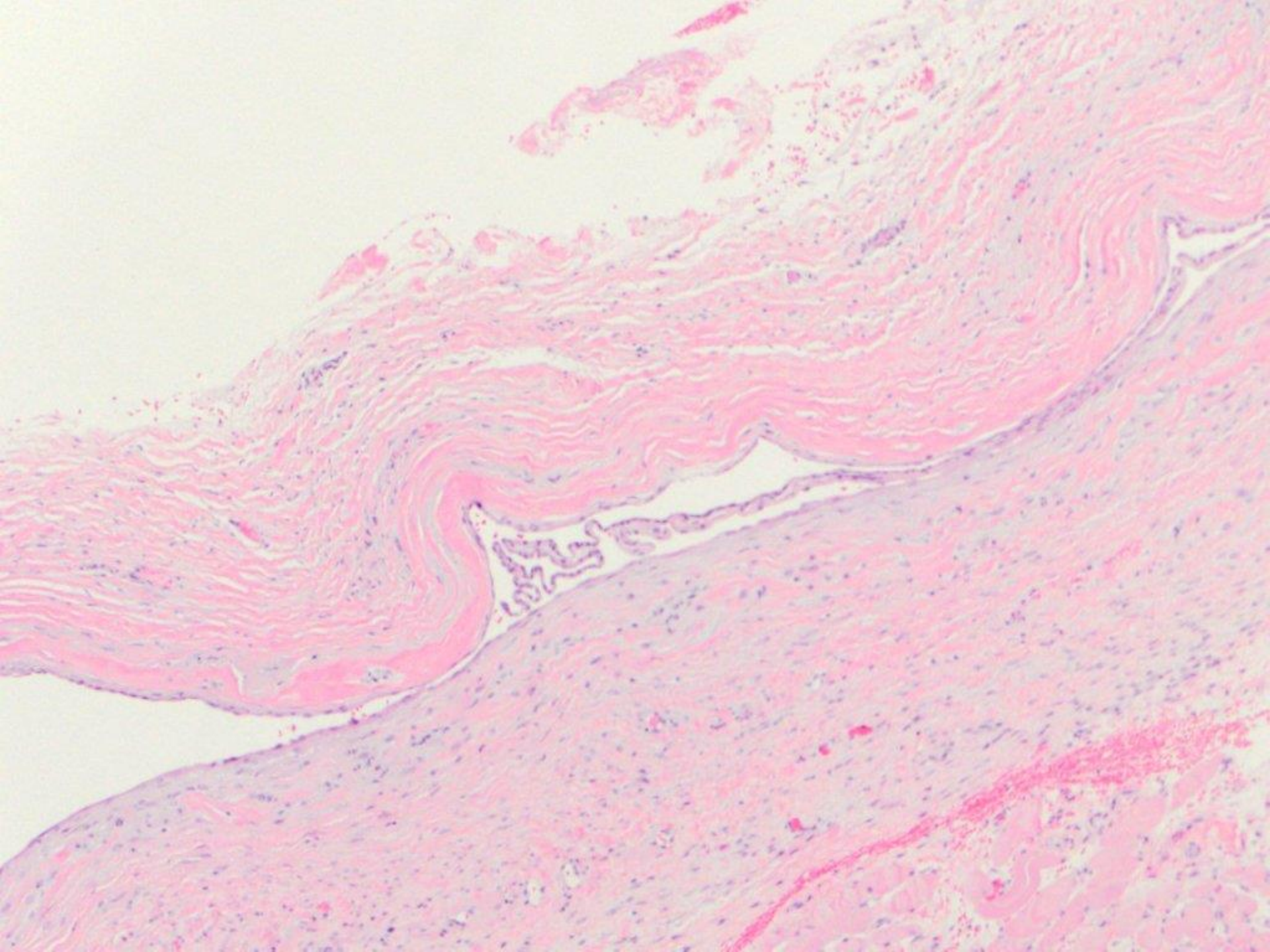


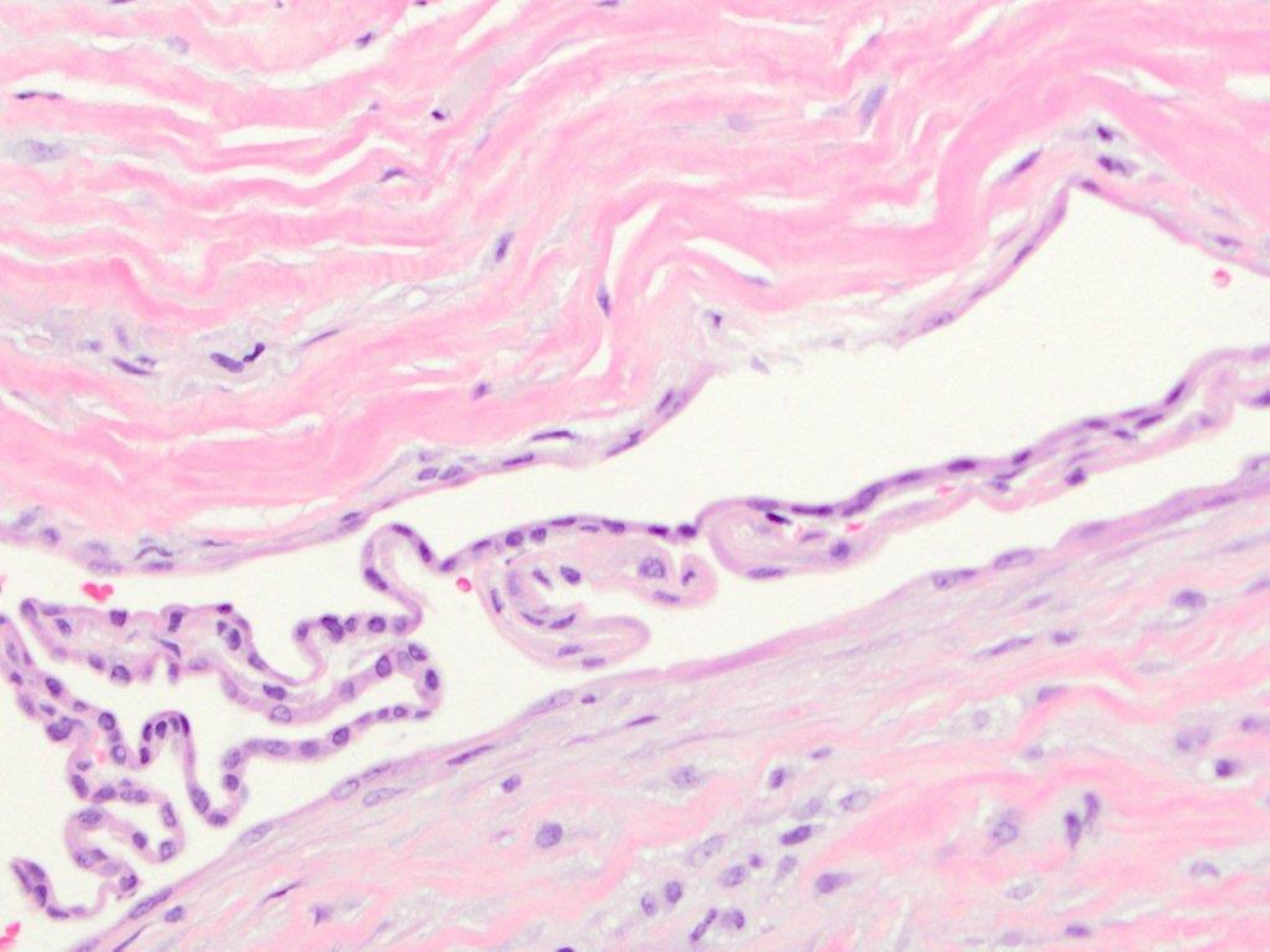


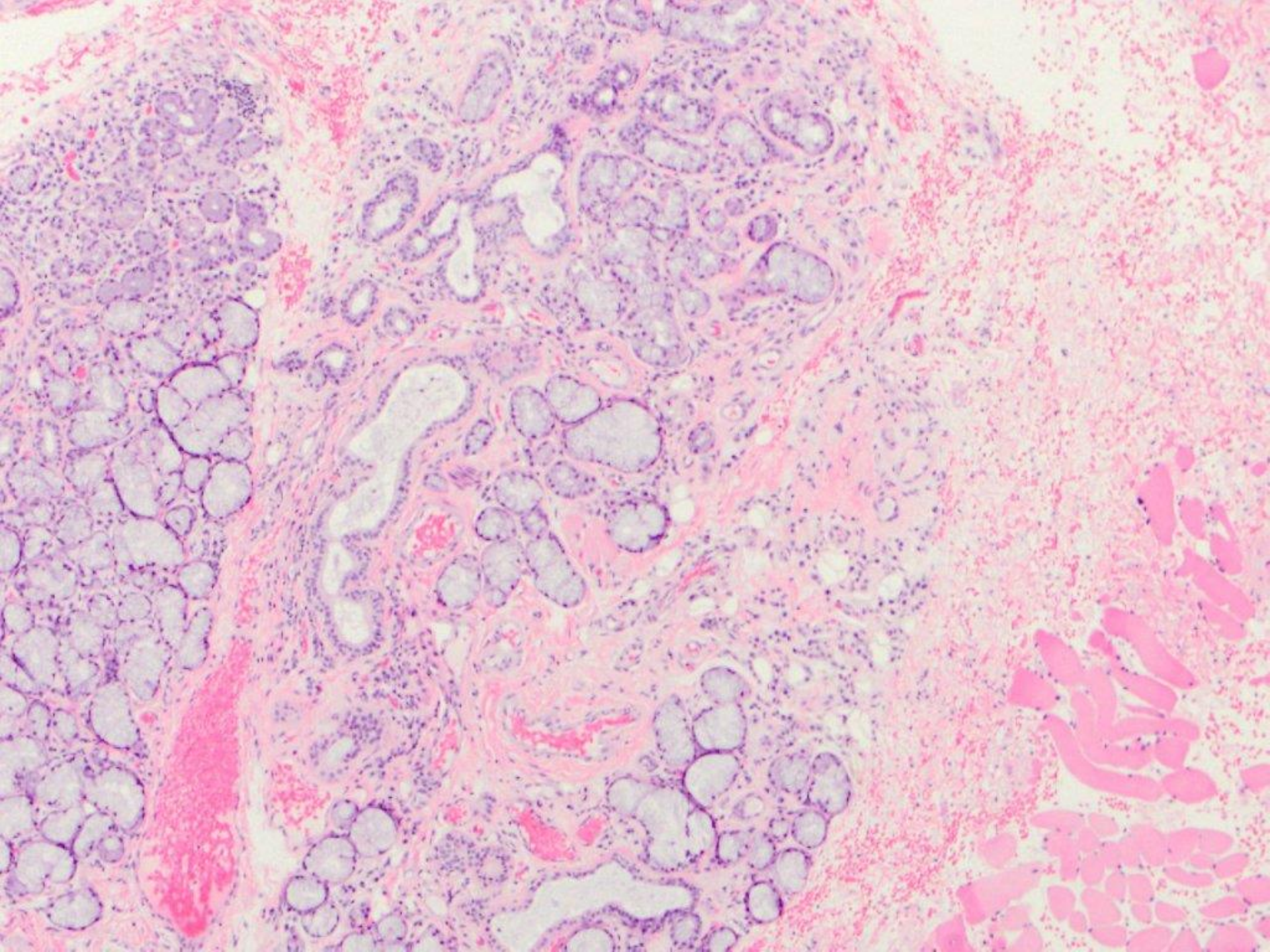


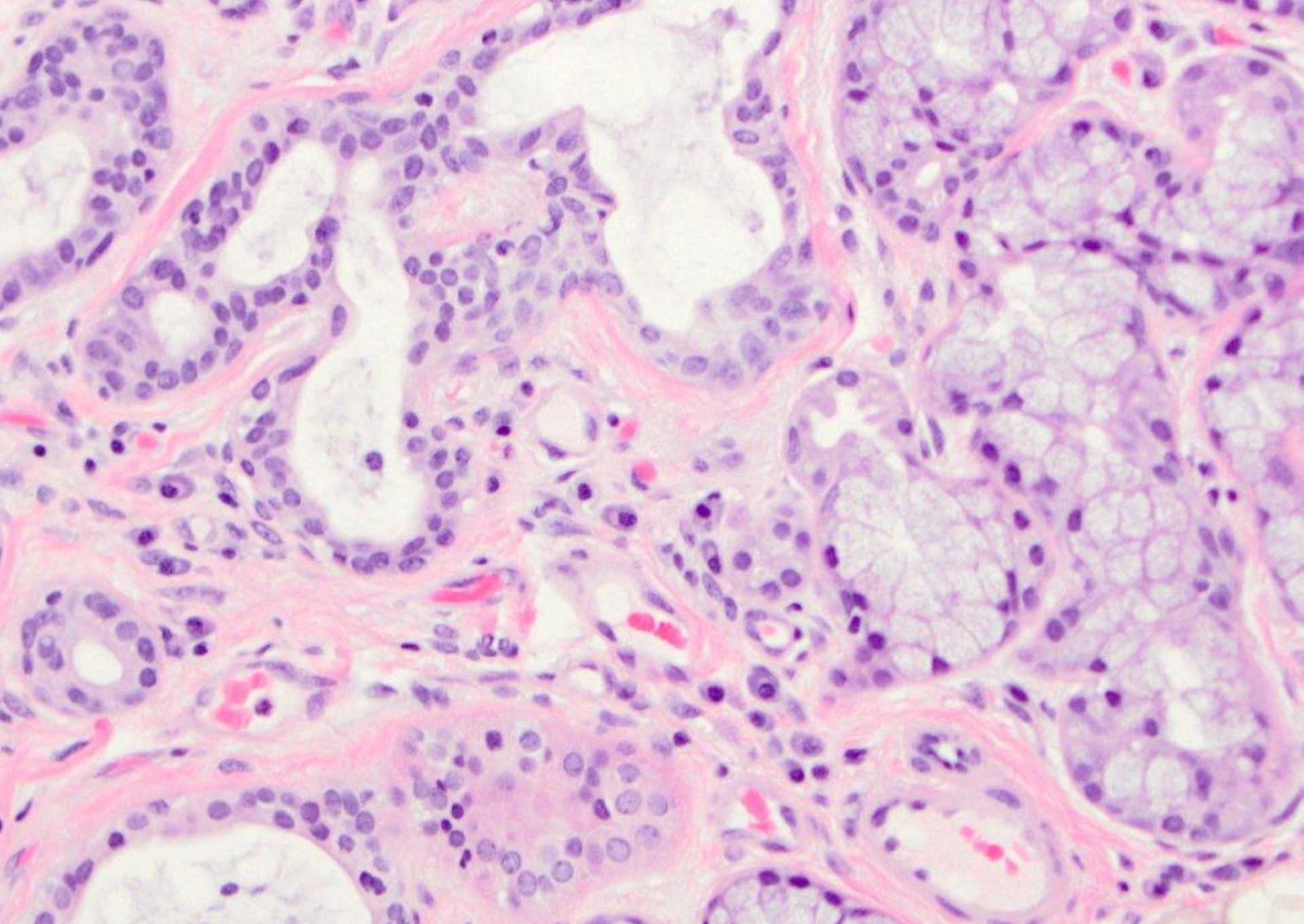
telangiectases



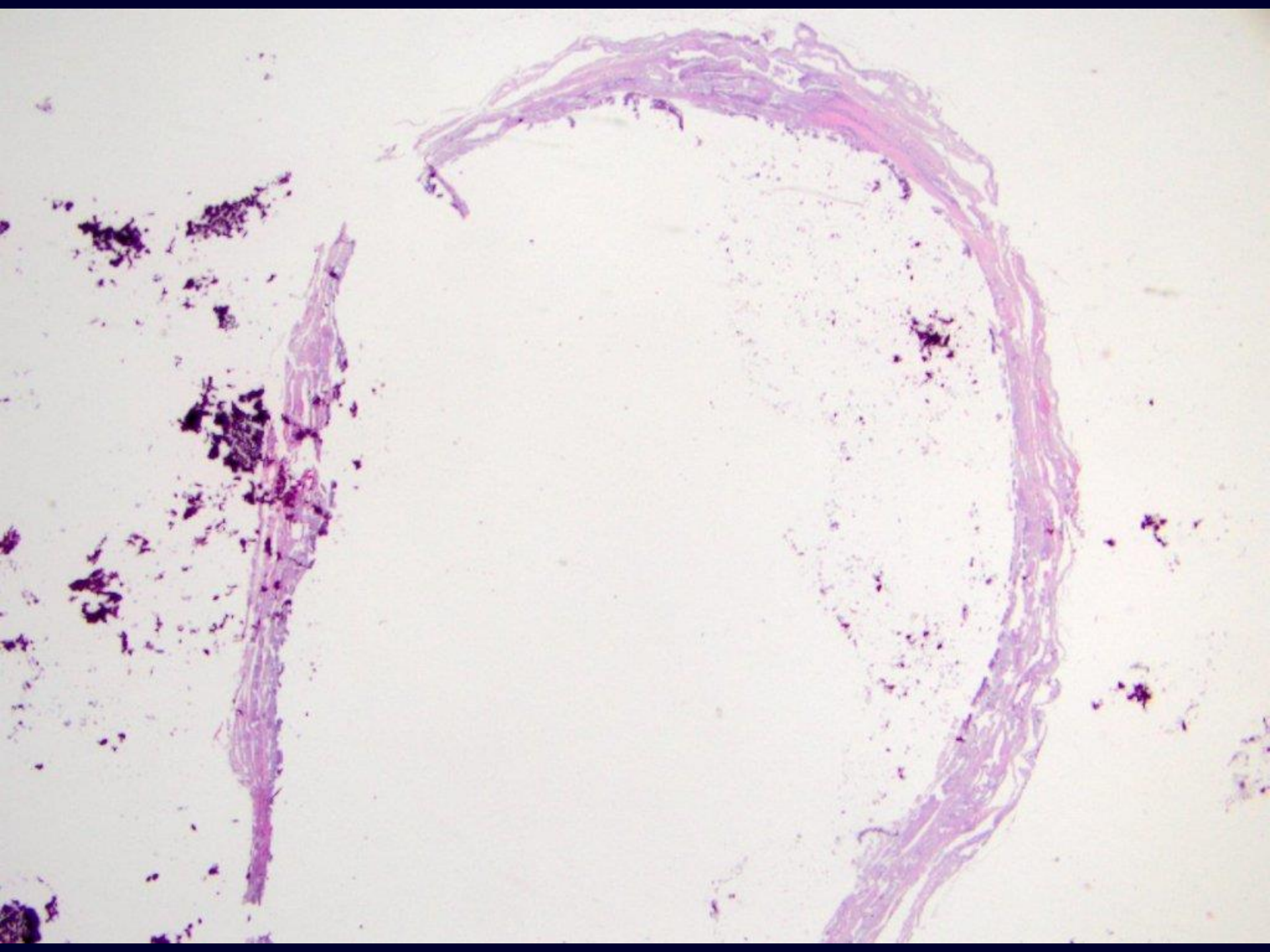


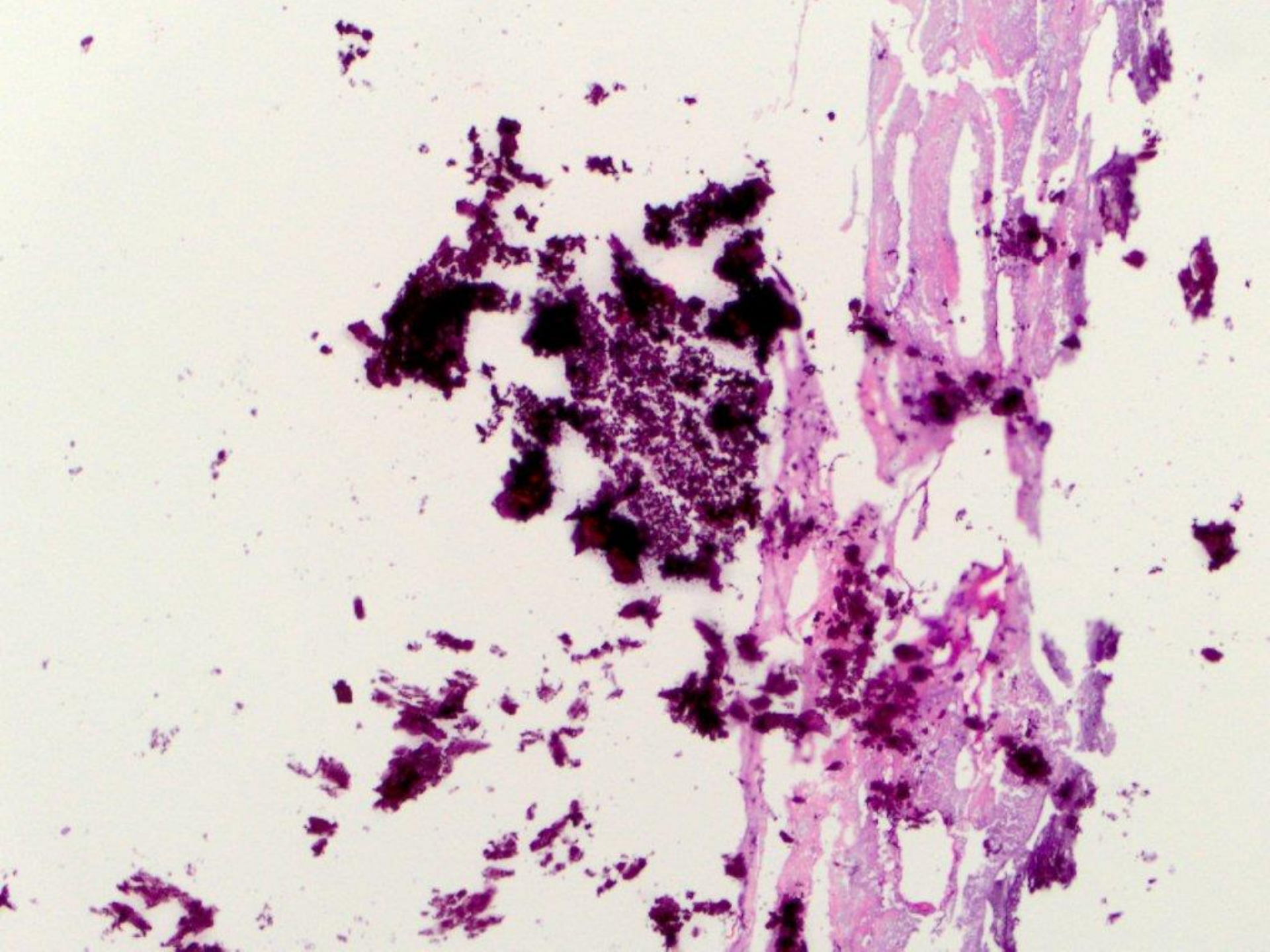


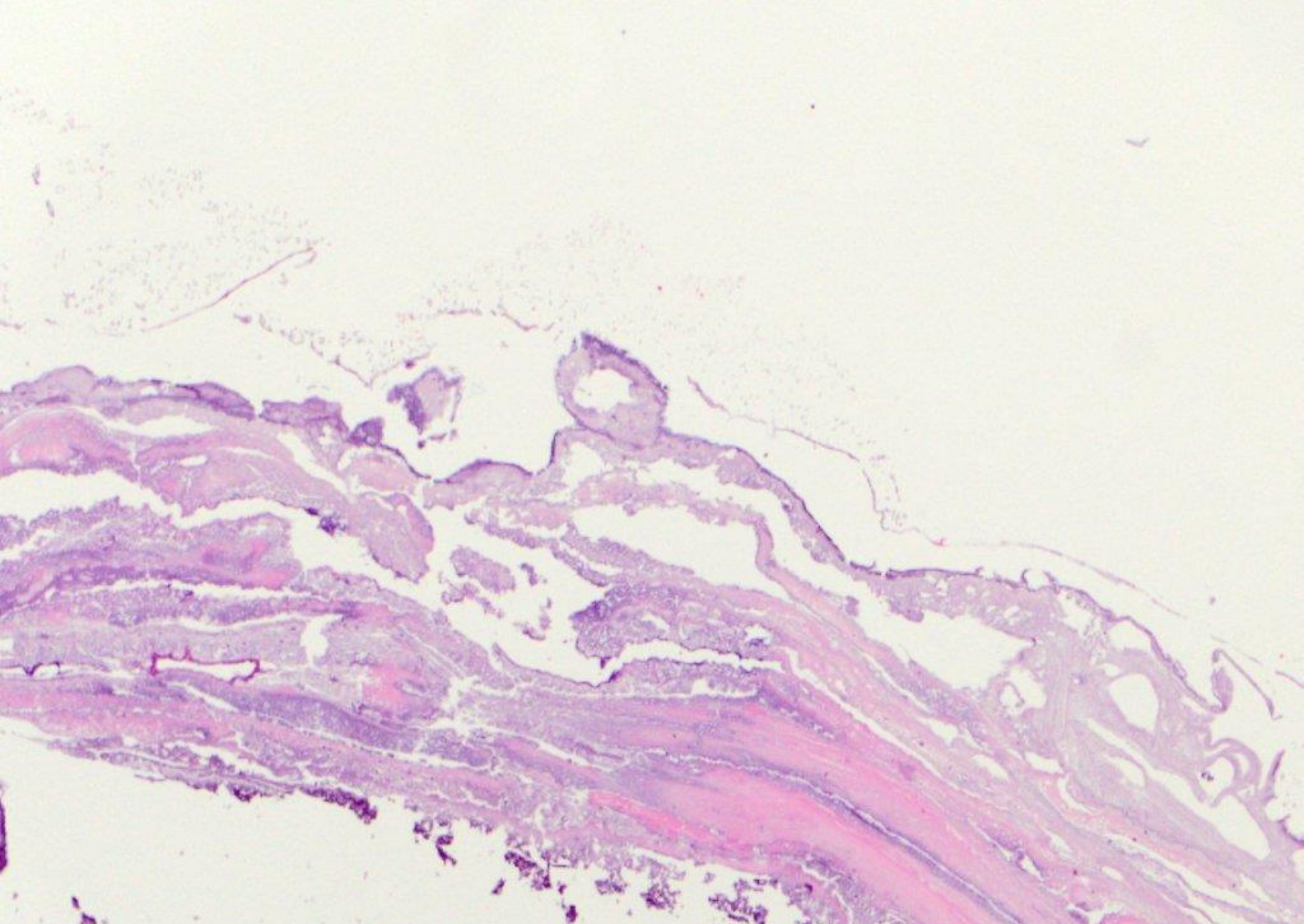




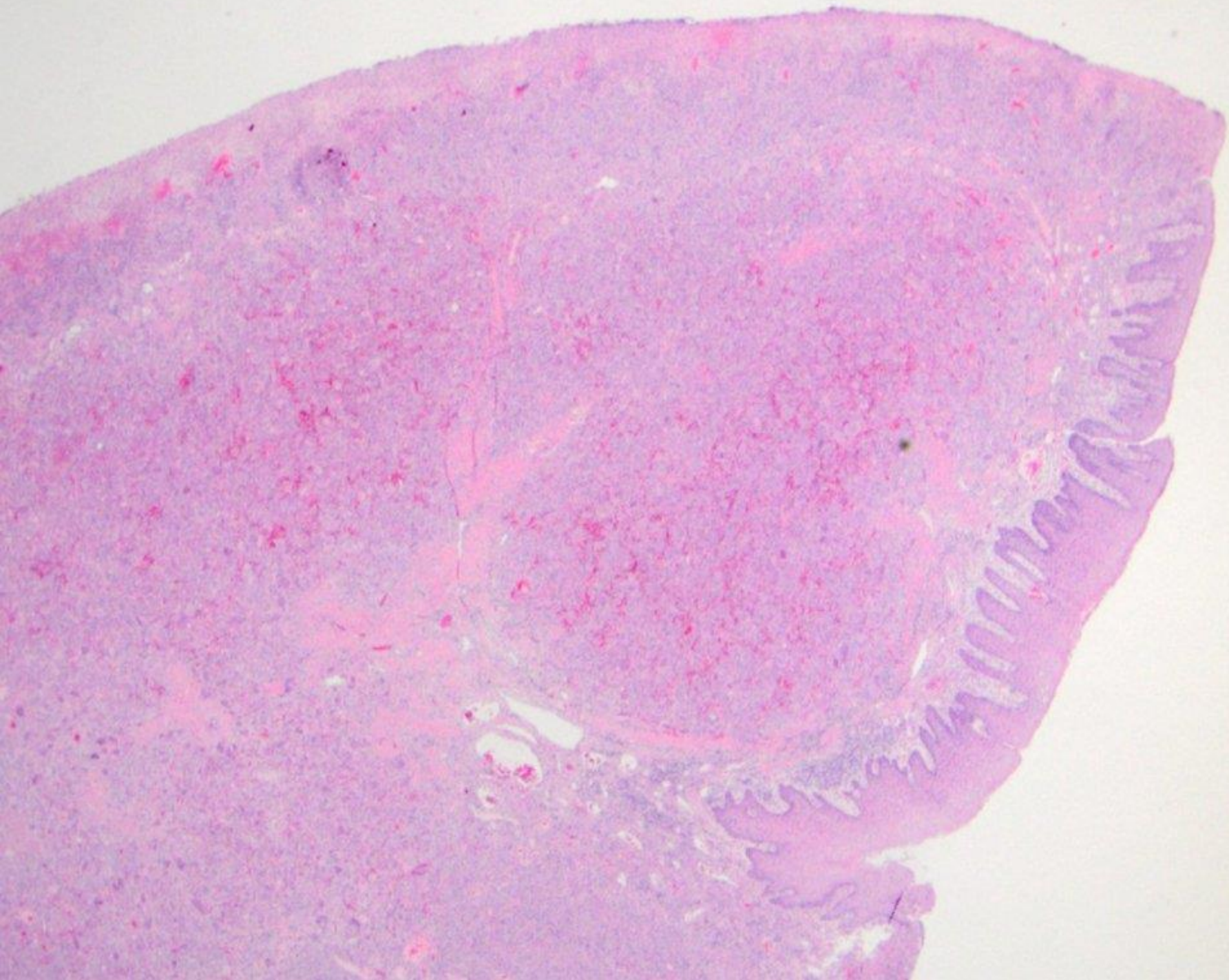
salivary duct cyst and sclerosing sialoadenitis

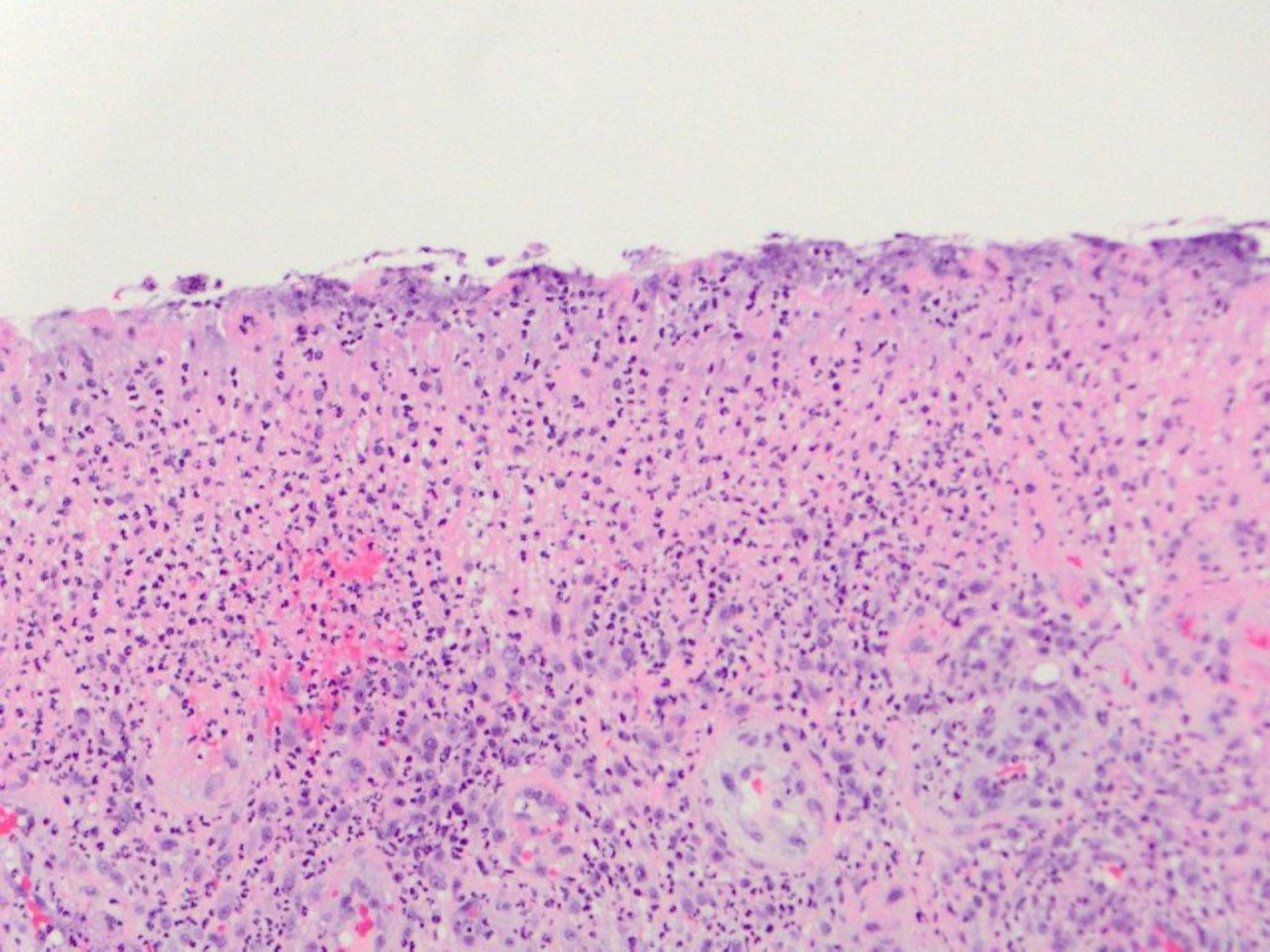


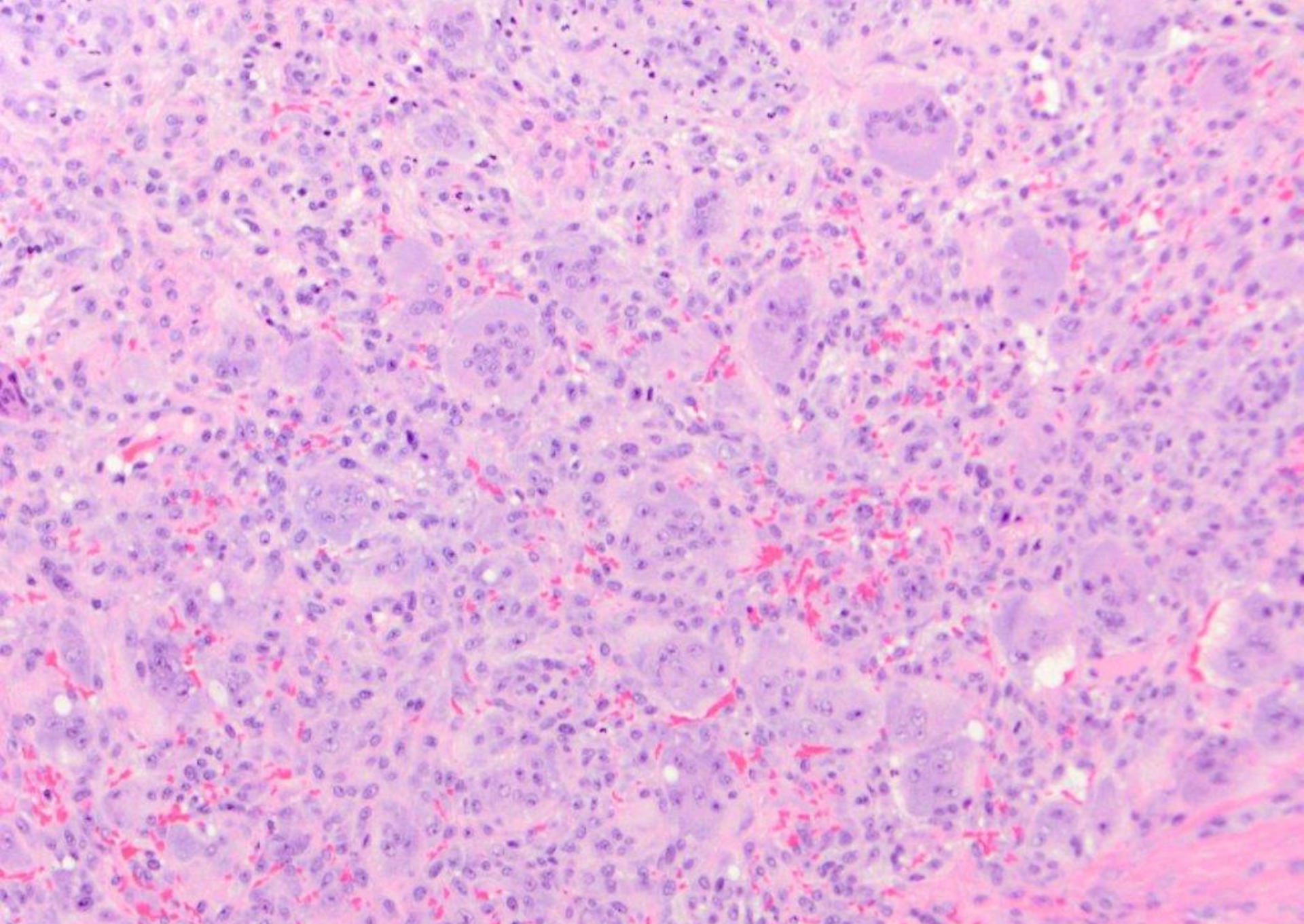




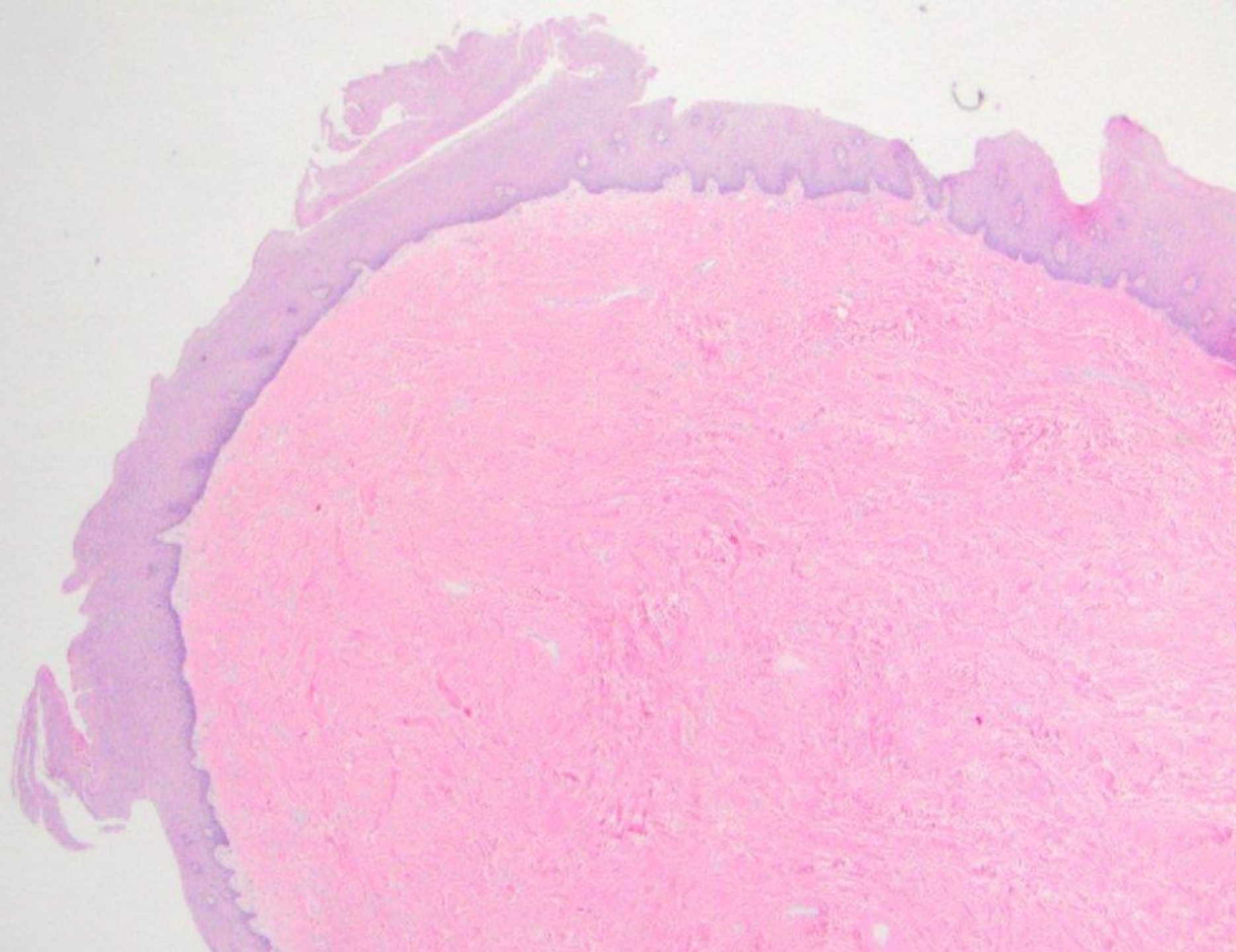
sialolith

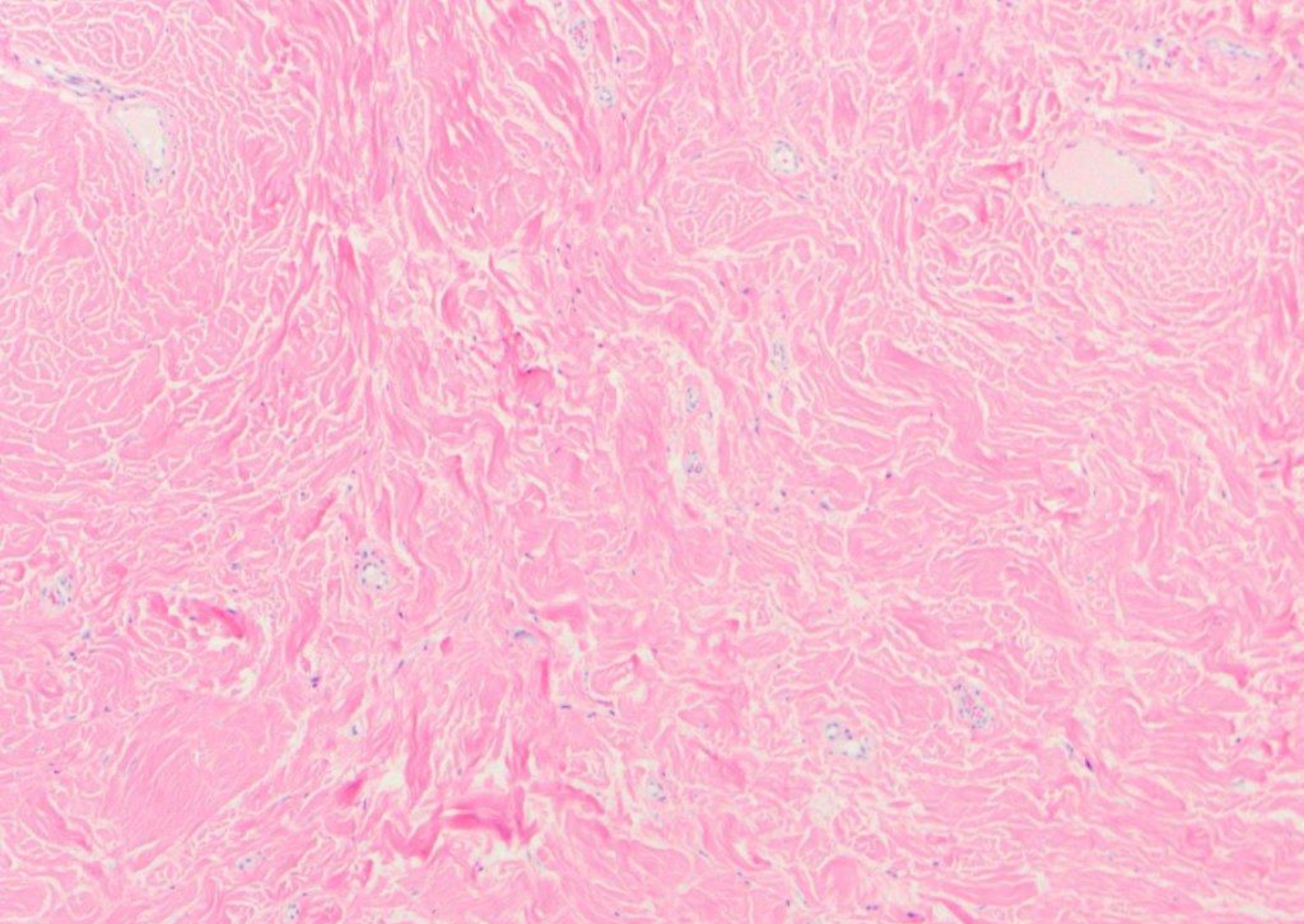




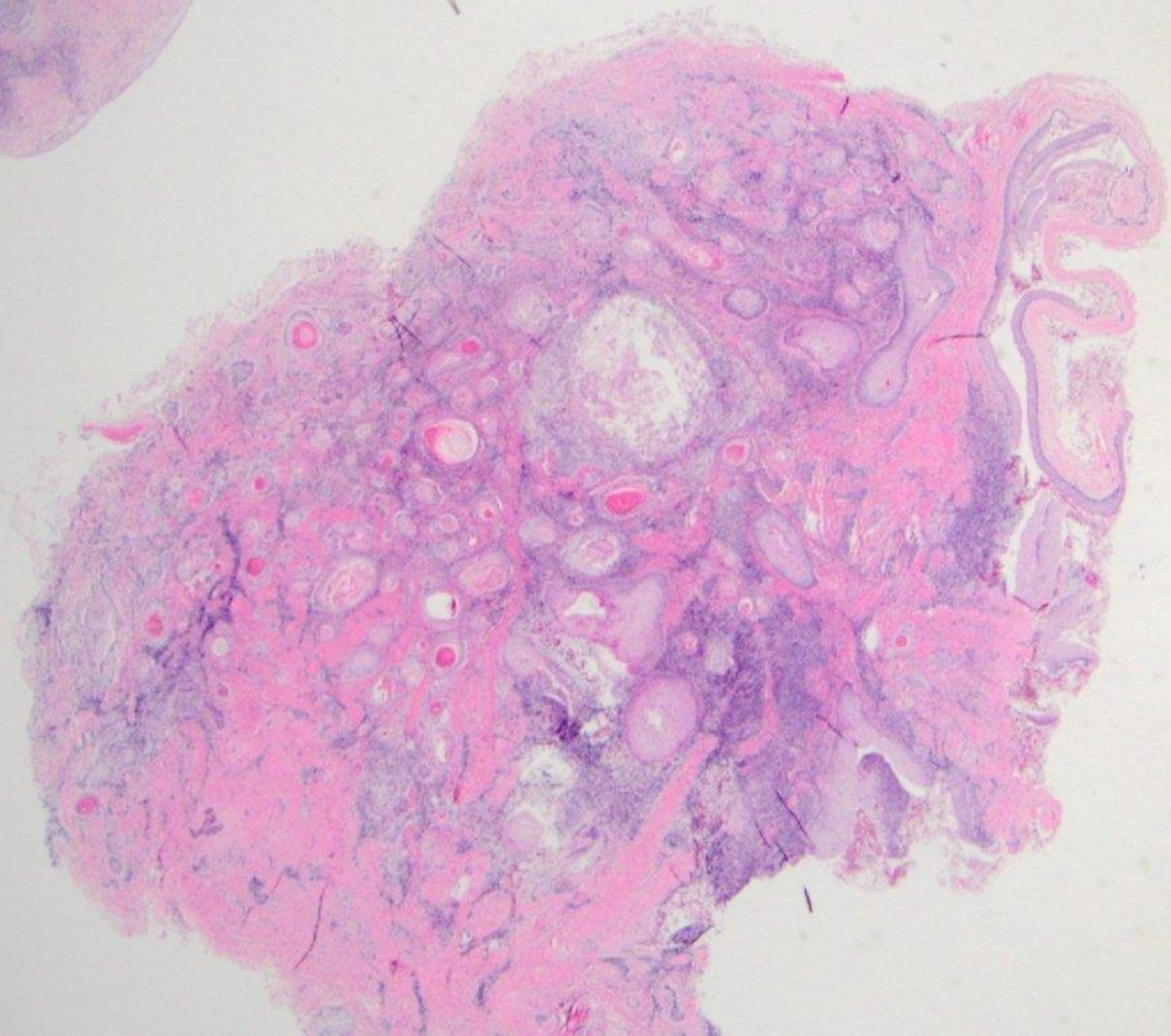


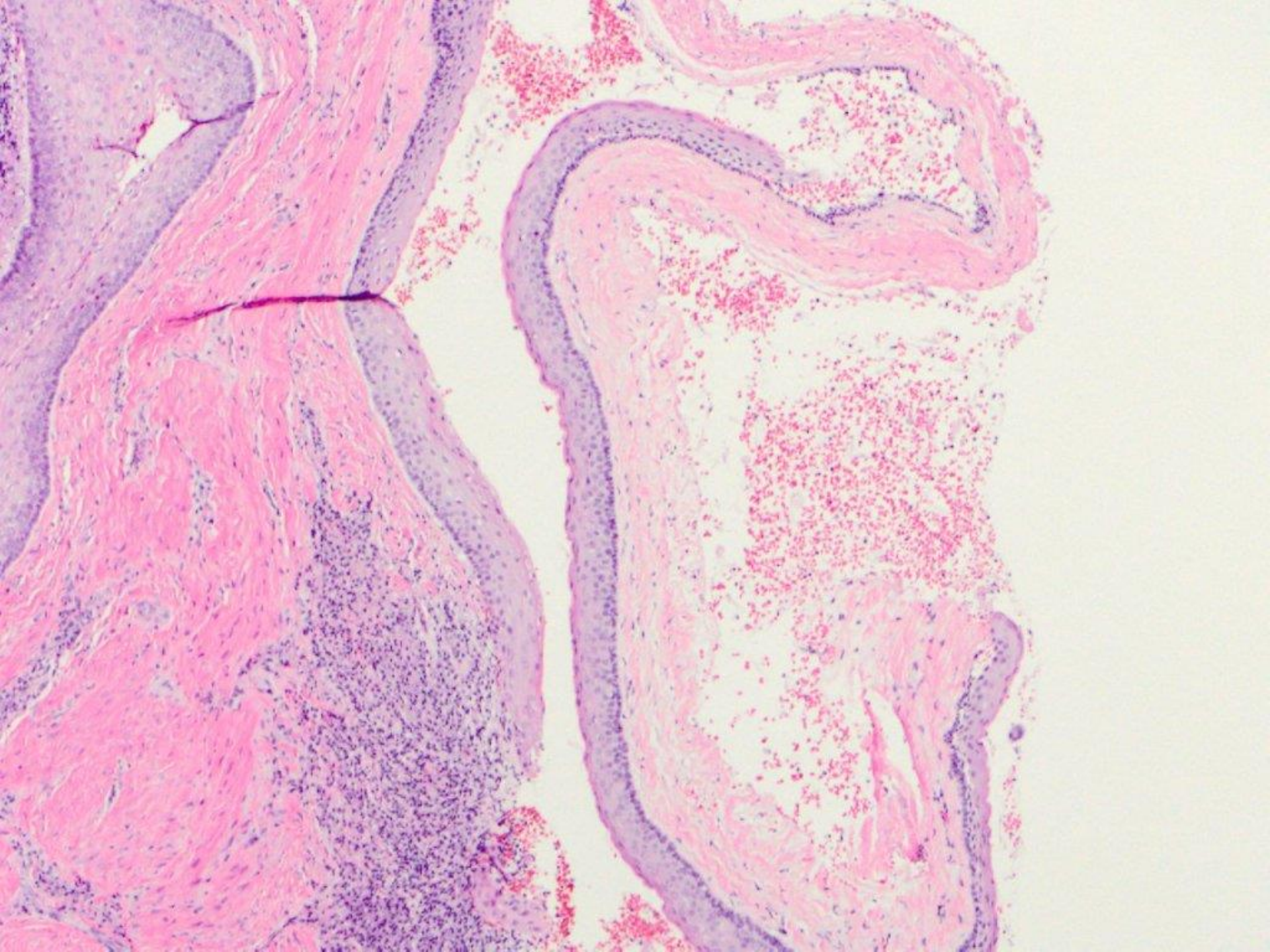
Ulcerated peripheral giant cell granuloma

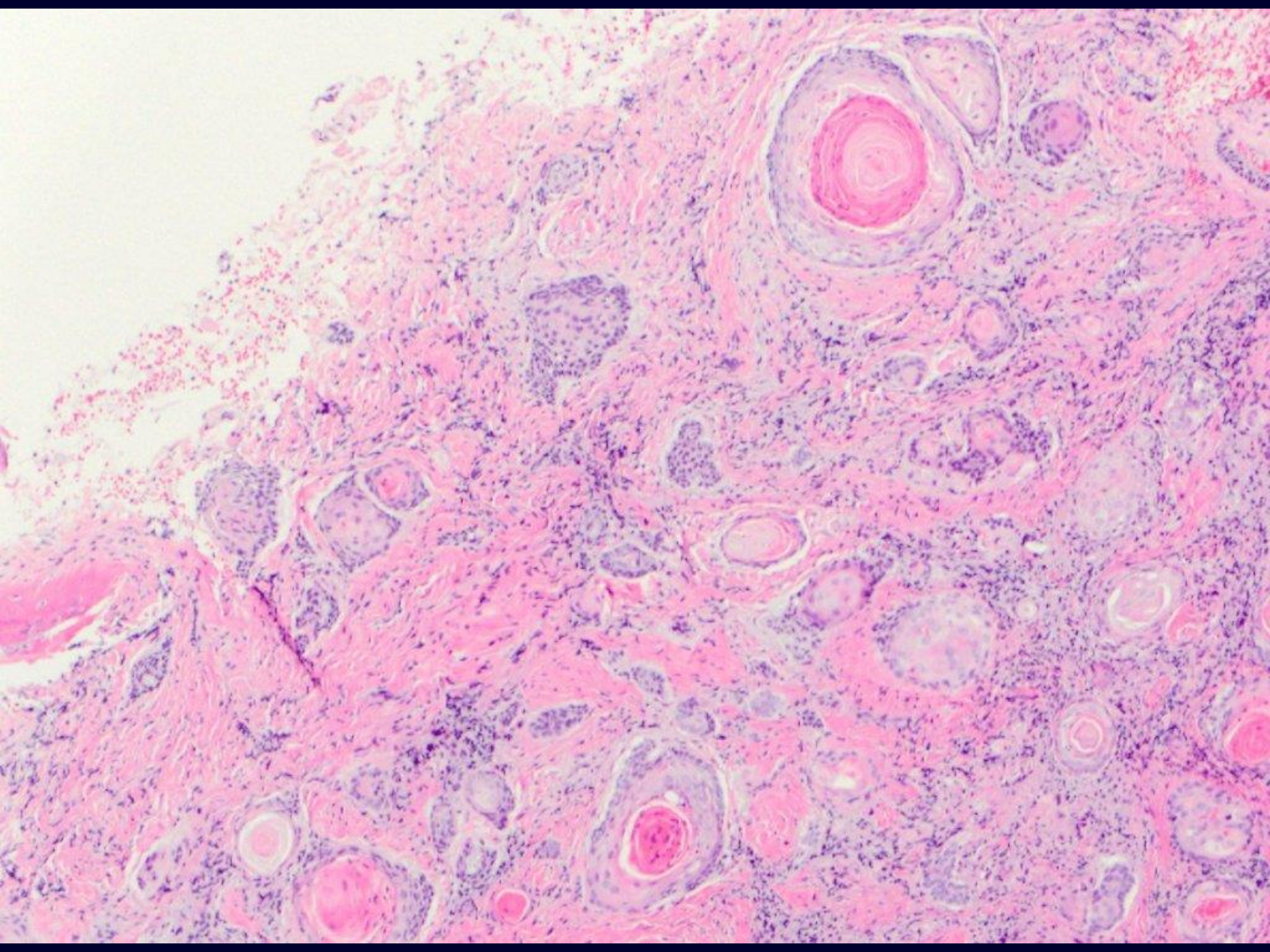


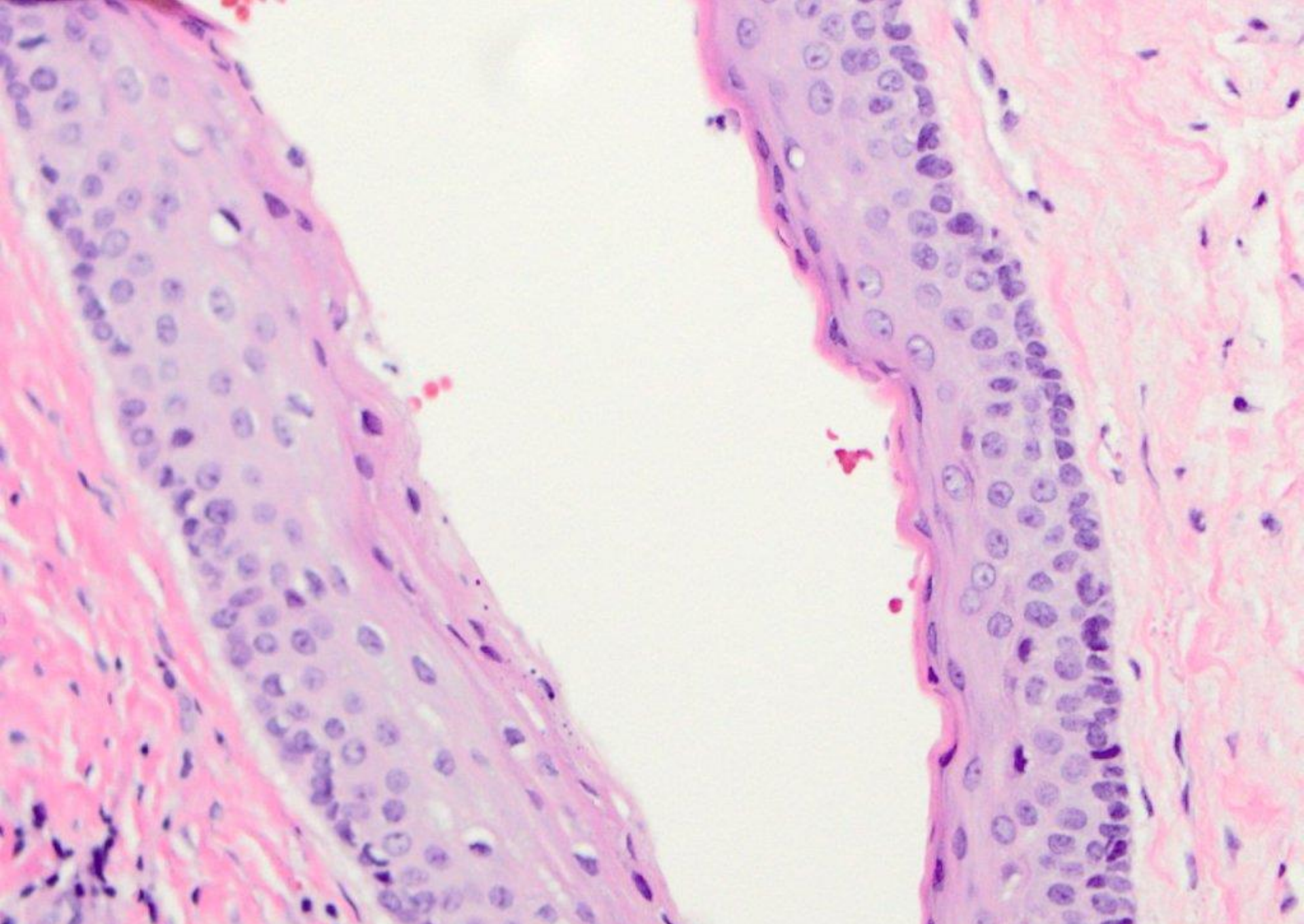


fibroma



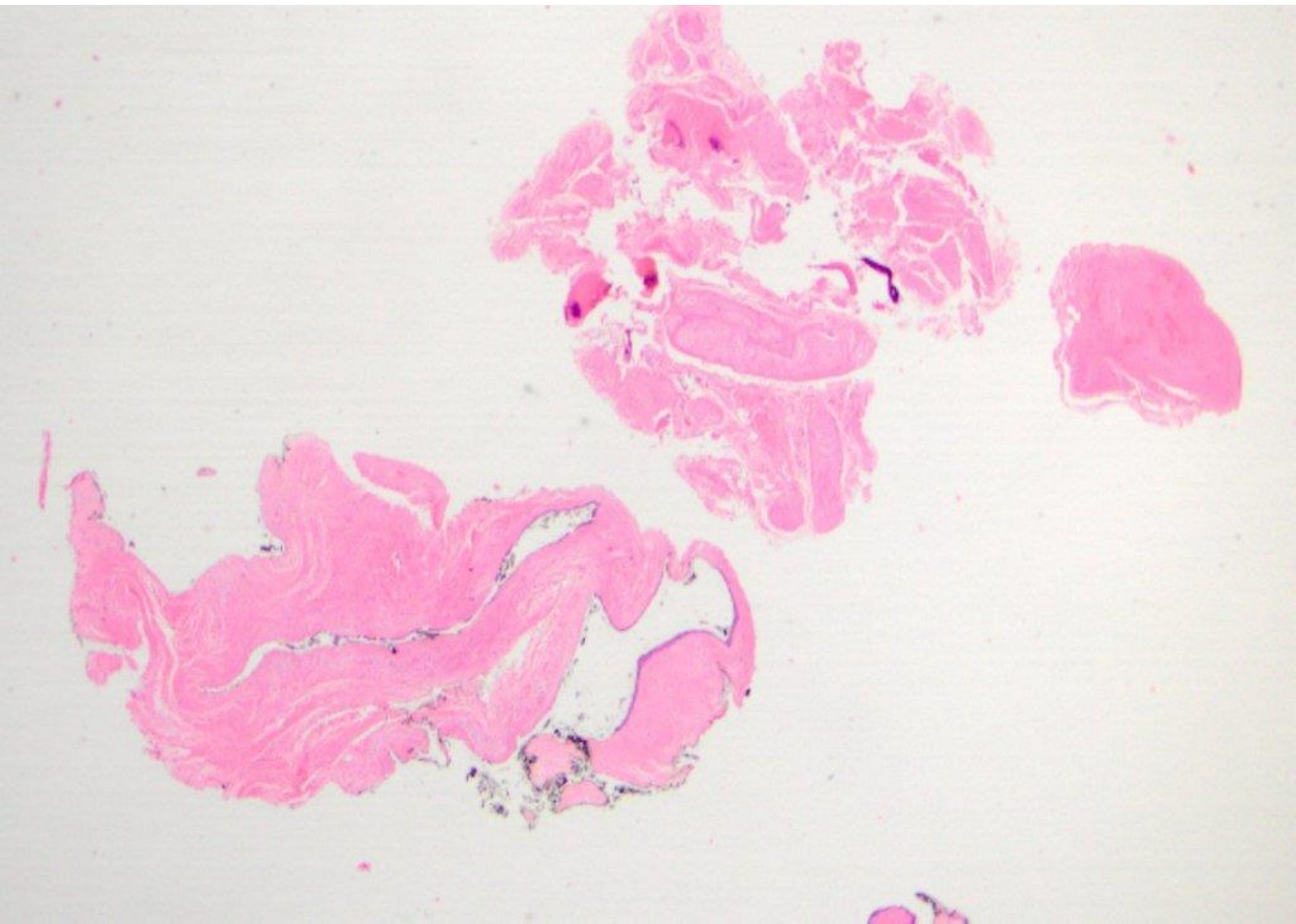


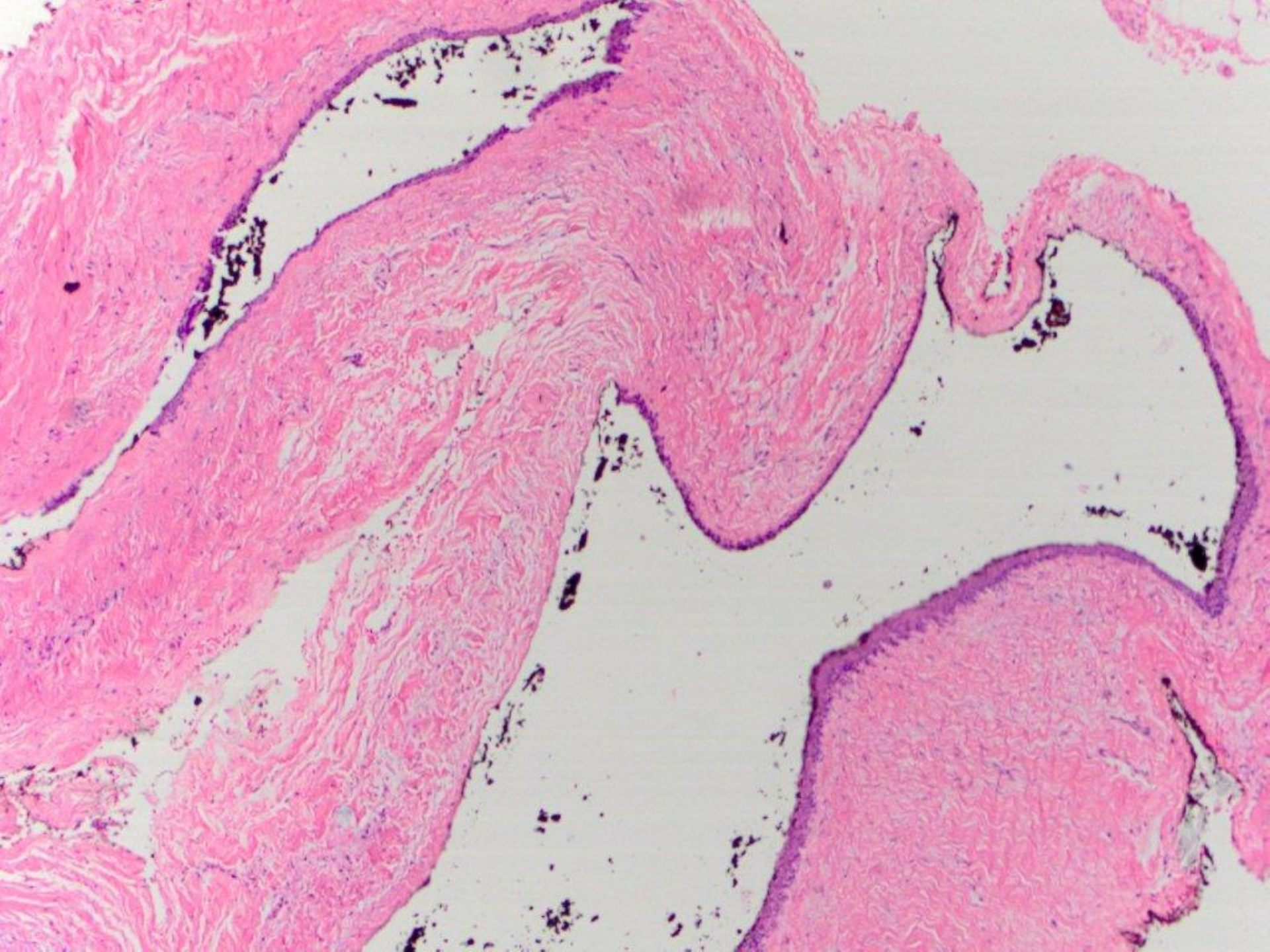


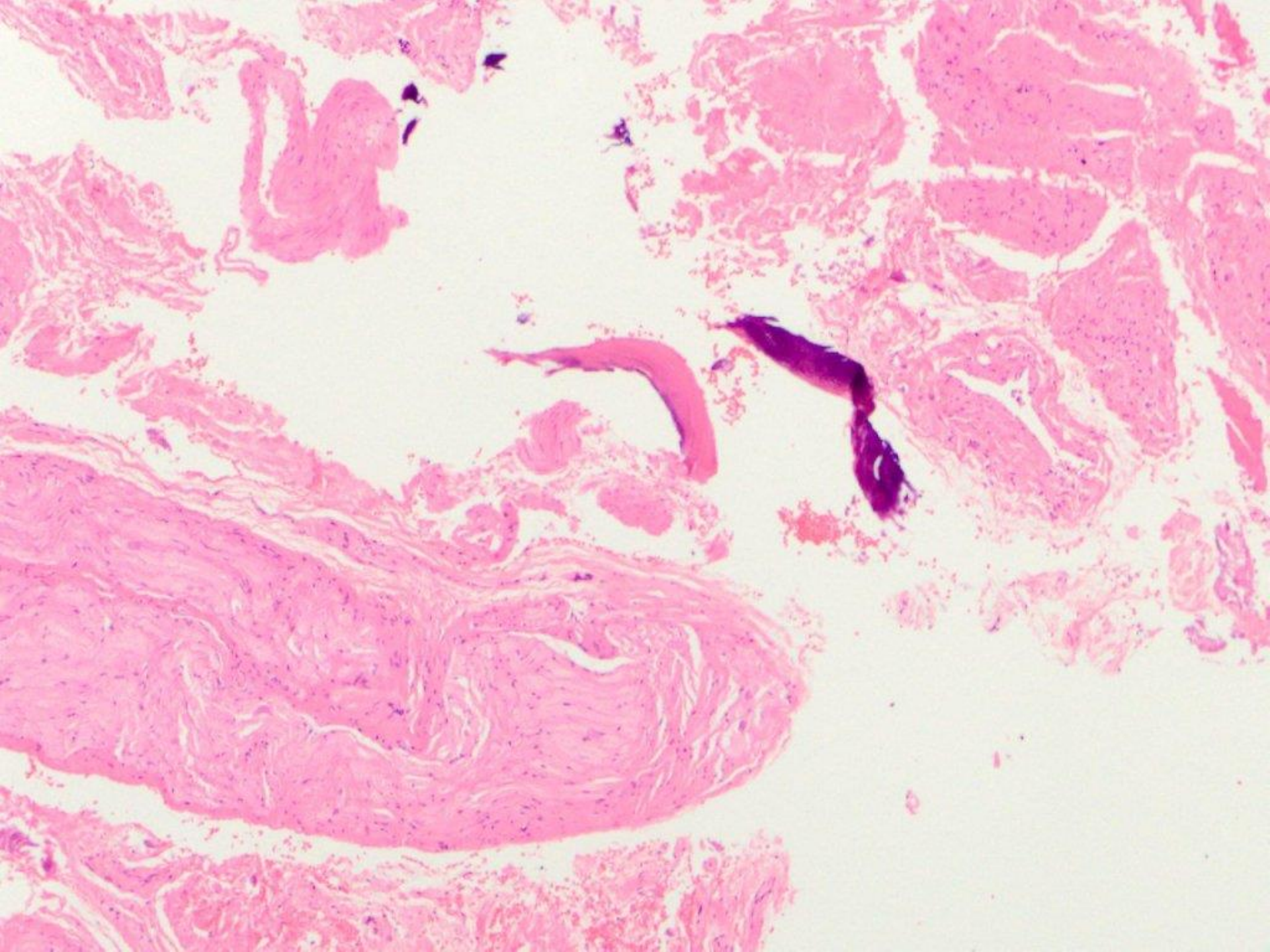


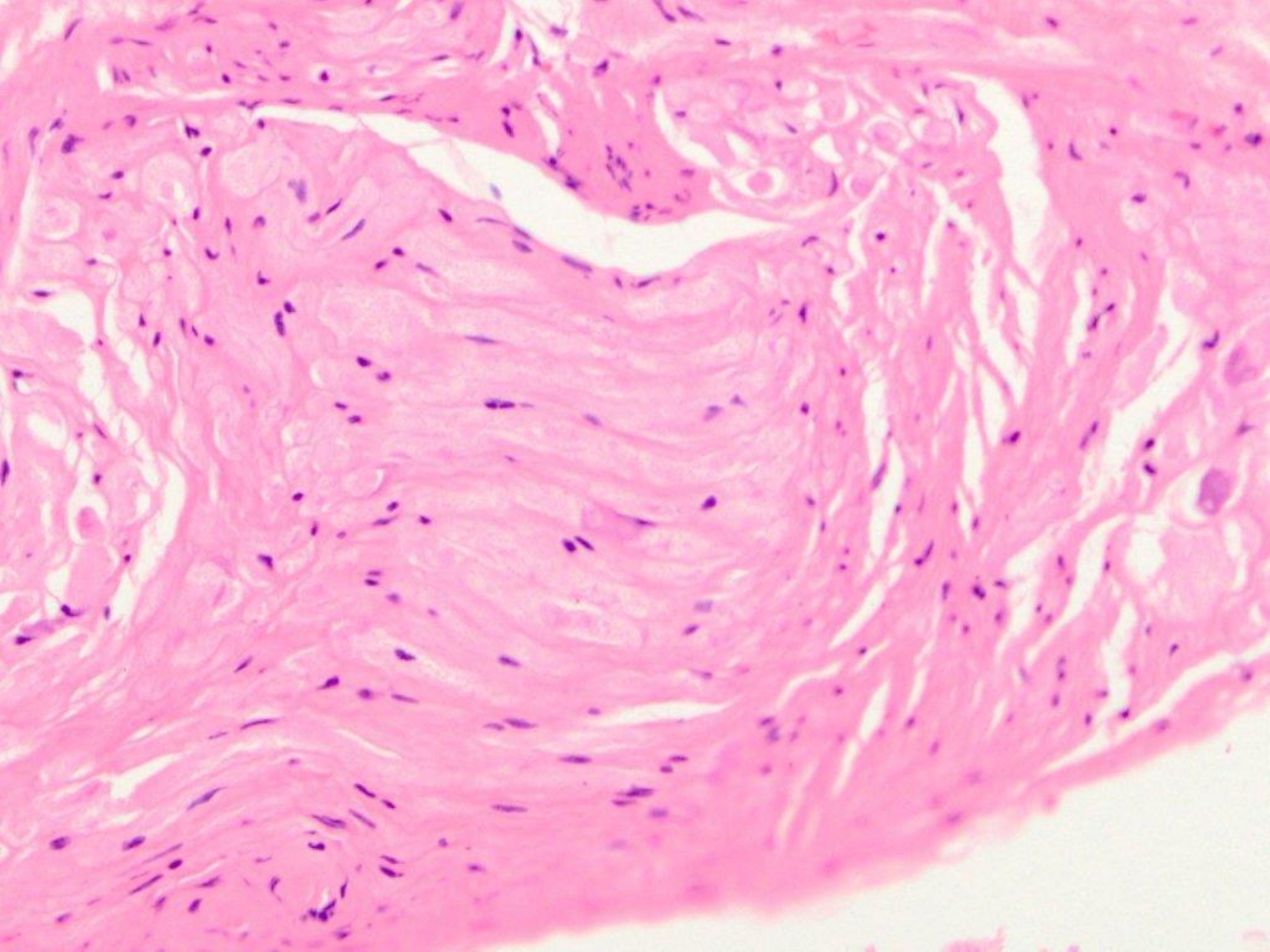
odontogenic keratocyst, with multiple daughter cysts

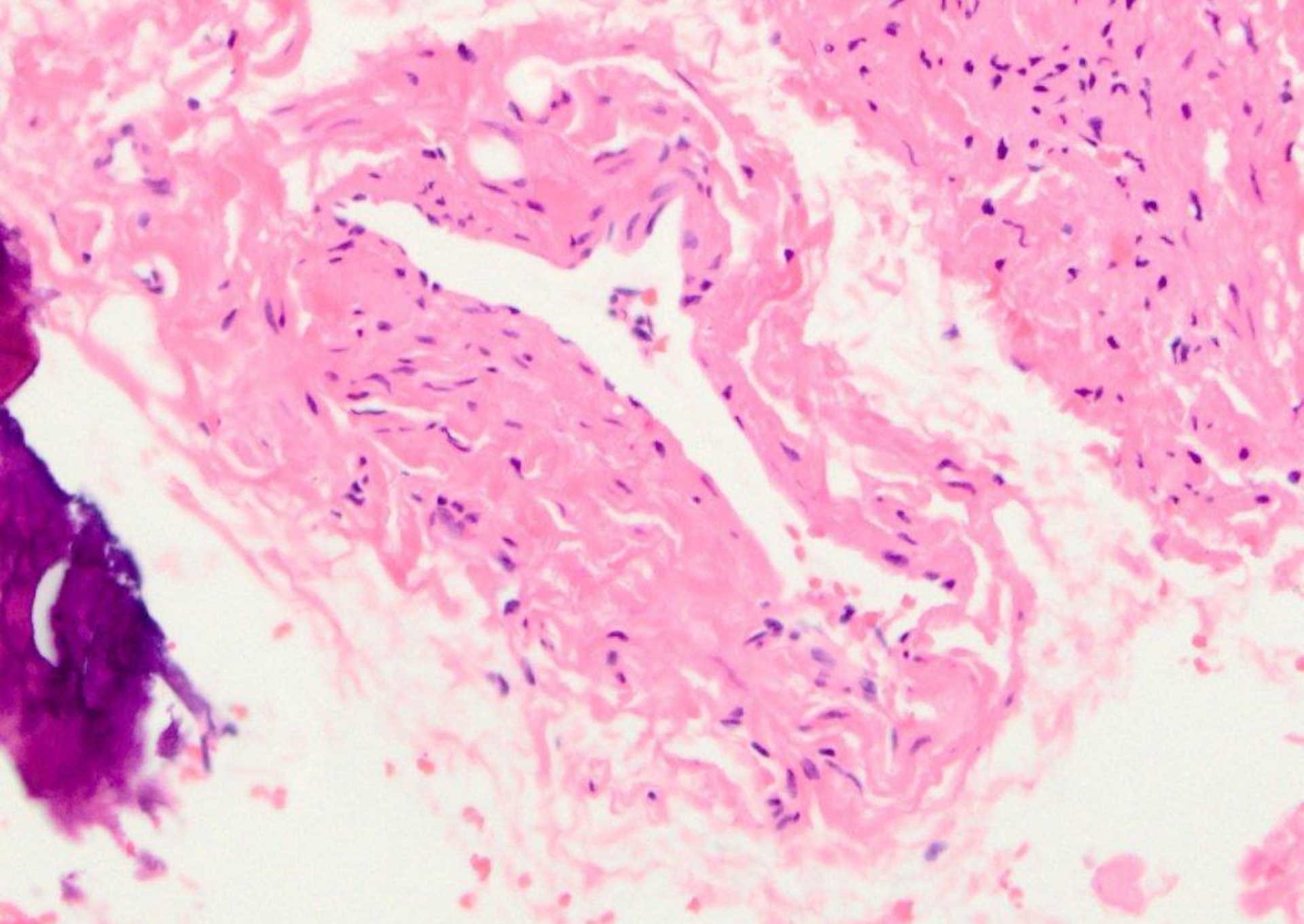
midline, anterior palate



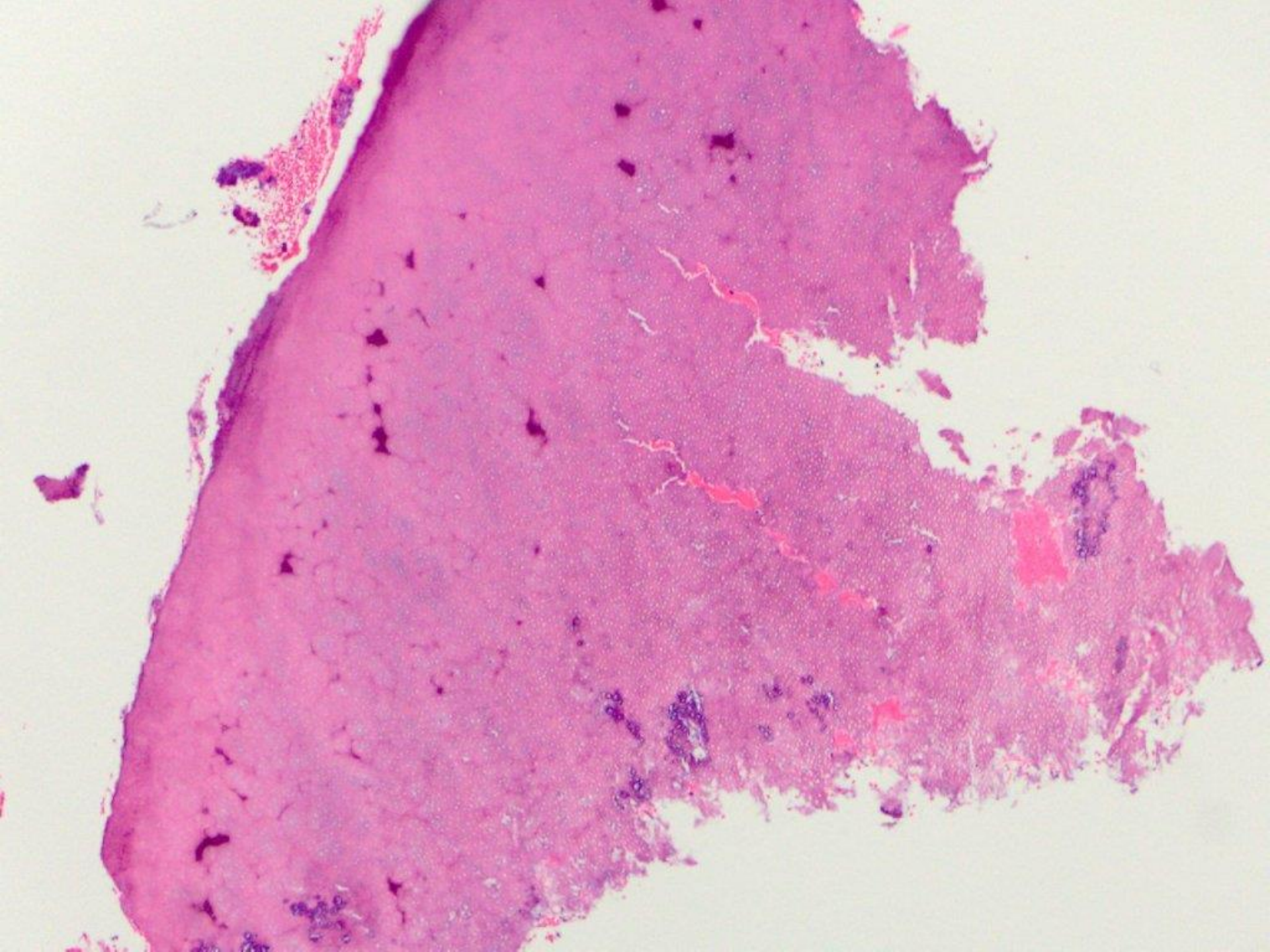


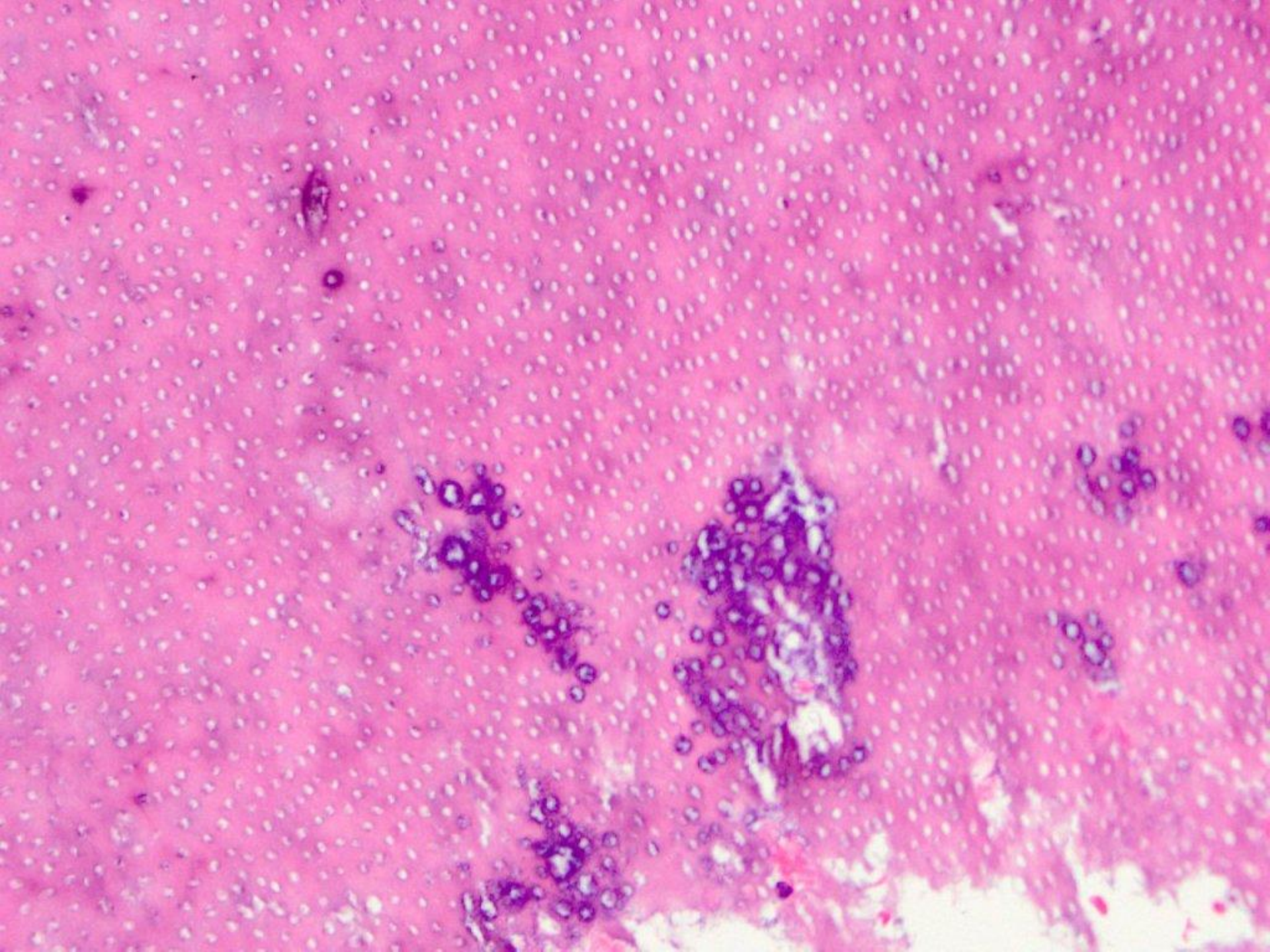


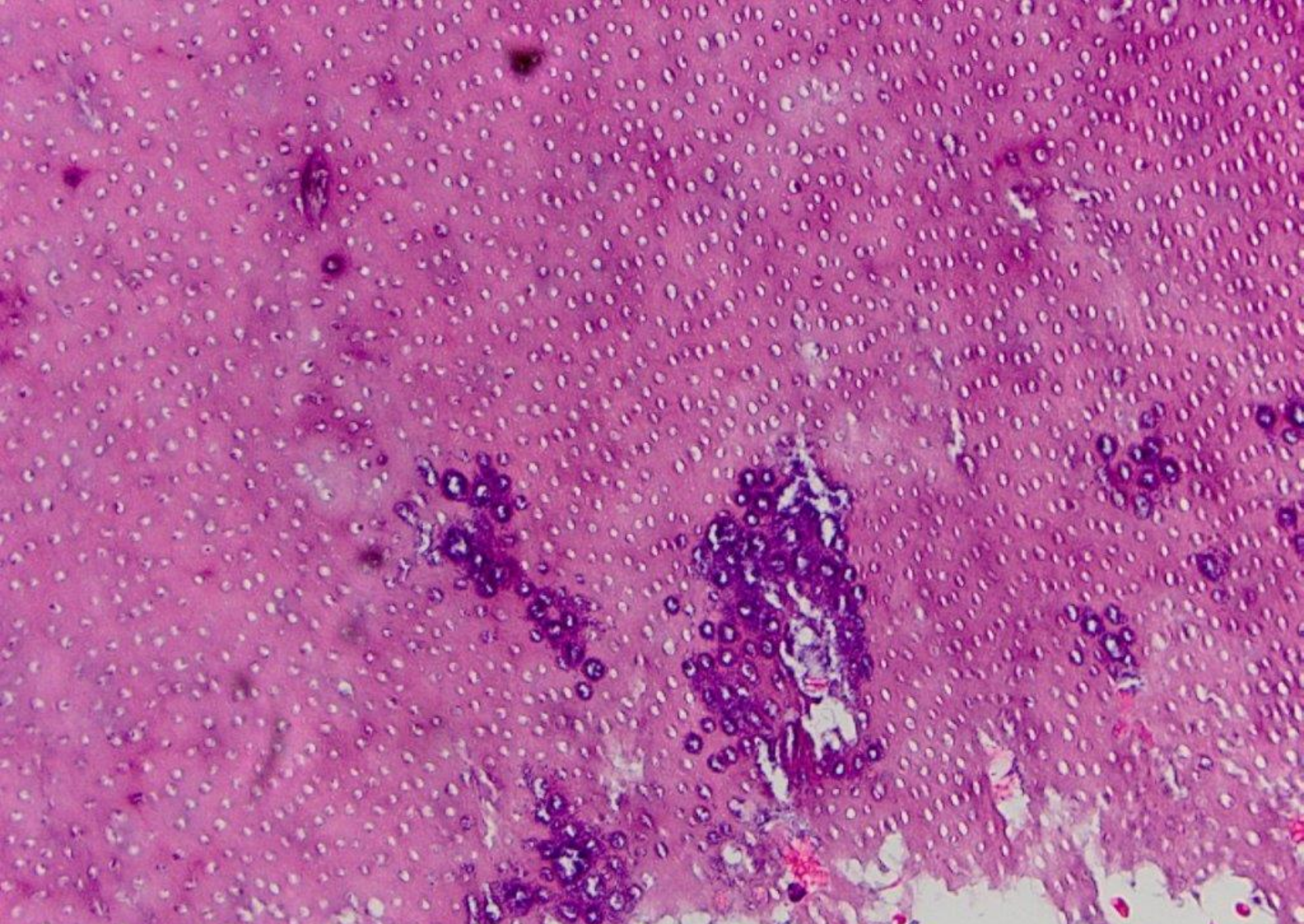




nasopalatine duct cyst







dentin, with bacterial debris (caries)